

# bradscholars

## Sequential cyclic changes of hair roots revealed by dermoscopy demonstrate a progressive mechanism of diffuse alopecia areata over time.

Item Type	Article
Authors	Zhang, X.;Ye, Y.;Zhu, Z.;Yang, Y.;Cao, H.;McElwee, Kevin J.;Ling, Y.
Citation	Zhang X, Ye Y, Zhu Z et al (2020) Sequential cyclic changes of hair roots revealed by dermoscopy demonstrate a progressive mechanism of diffuse alopecia areata over time. <i>Experimental Dermatology</i> . 29: 223-230.
DOI	<a href="https://doi.org/10.1111/exd.13799">https://doi.org/10.1111/exd.13799</a>
Rights	© 2018 Wiley This is the peer reviewed version of the following article: Zhang X, Ye Y, Zhu Z et al (2020) Sequential cyclic changes of hair roots revealed by dermoscopy demonstrate a progressive mechanism of diffuse alopecia areata over time. <i>Experimental Dermatology</i> . 29: 223-230. which has been published in final form at <a href="https://doi.org/10.1111/exd.13799">https://doi.org/10.1111/exd.13799</a> . This article may be used for non-commercial purposes in accordance with Wiley Terms and Conditions for Self-Archiving.
Download date	2026-04-21 11:10:22
Link to Item	<a href="http://hdl.handle.net/10454/17237">http://hdl.handle.net/10454/17237</a>

**Sequential cyclic changes of hair roots revealed by dermoscopy  
demonstrate a progressive mechanism of diffuse alopecia areata over  
time**

Xingqi Zhang<sup>1\*</sup>, Yanting Ye<sup>1</sup>, Zhaohui Zhu<sup>1</sup>, Yuqing Yang<sup>1</sup>, Hui Cao<sup>1</sup>, Kevin J.

McElwee<sup>2</sup>, Yunxia Lin<sup>1</sup>

<sup>1</sup>Department of Dermatology, First Affiliated Hospital of Sun Yat-sen University,  
Guangzhou, Guangdong 510080, People's Republic of China.

<sup>2</sup>Centre for Skin Sciences, The University of Bradford, West Yorkshire, UK.

\*Corresponding author: Prof. Xingqi Zhang, M.D., Ph.D. Department of  
Dermatovenereology, The First Affiliated Hospital, Sun Yat-sen University,  
Guangzhou, 510080, Guangdong, China. (E-mail: xingqi.zhang@aliyun.com)

**Key words:** Hair roots; alopecia areata; diffuse alopecia areata; alopecia areata  
incognita; dermoscopy; trichoscopy; acute telogen effluvium; club hairs; catagen;  
anagen.

**Running title:** Hair roots in diffuse alopecia areata

Total word count: 3480

Disclosures: K McElwee is Chief Scientific Officer for Replicel Life Sciences Inc. All other authors declare no conflict of interest.

Author Contributions Statement: X.Z. and K.J.M. designed the research study. X.Z., Y.Y., Z.Z., H.C., and Y.L. performed the research, X.Z. performed the data analysis. X.Z drafted the manuscript, which was commented on and edited by K.J.M. All authors approved the submitted manuscript.

## **Abstract**

**Background:** Diffuse alopecia areata (DAA) often leads to a complete hair shedding within a few months. **Objective:** To explore features and mechanisms underlying DAA. **Materials and methods:** Scalp and hair root dermoscopy were conducted on 23 DAA patients throughout the disease process, 20 patchy AA (PAA) patients, 23 acute telogen effluvium (ATE) patients, and 10 normal controls. Histopathology was also evaluated. **Results:** We found almost all hair roots were anagen in early stage DAA in 18 patients (18/23, 78.3%) within the first 4-8 weeks after hair loss onset. Anagen effluvium (~4 weeks) was followed by catagen (~4 weeks) and then telogen/exogen (~8 weeks) effluvium with overlap. Hair root and proximal hair shaft depigmentation was more prominent in later DAA disease stages. Black dots, exclamation mark hairs and inconsistent thickness of hair shafts were found more often in early than later DAA ( $P_s < 0.01$ ). Early DAA histopathology revealed more prominent inflammation and hair follicle regression than that observed in the later stages. PAA patients showed mixed anagen, catagen and telogen hair roots while ATE patients showed increased exogen and mildly decreased hair root pigmentation. **Conclusion:** Sequential cyclic staging of shed hairs in DAA indicates the insult may be hair-cycle specific. We suggest that DAA is initially an anagen effluvium disease involving an intense inflammatory insult, later progressing to a brief catagen effluvium, and then to telogen effluvium with premature exogen, in later stages of DAA.

## 1. Introduction

Alopecia areata (AA) is a non-scarring inflammatory hair loss disease characterized by inflammatory infiltration of anagen hair follicles (HF) and alteration of the hair cycles.<sup>[1-3]</sup> Usually, AA hair loss presents as patchy,<sup>[4,5]</sup> but in a small percentage of patients it can be an acute diffuse hair loss over the scalp which may last for 3-5 months. The hair loss can progress to alopecia totalis,<sup>[6]</sup> but more commonly newly grown hairs appear before all the original hairs are shed. This clinical presentation is termed diffuse AA (DAA)<sup>[7]</sup>.

Telogen and exogen hair roots have been found in patients with acute telogen effluvium, androgenetic alopecia, and in normal individuals.<sup>[8,9]</sup> In contrast, both anagen and telogen hairs have been found in patients with DAA,<sup>[10,11]</sup> although there has been confusion about the timing of hair root types and the exact percentage of anagen and telogen hairs.<sup>[12,13]</sup> In comparison, Rebora and colleagues suggest AA incognita (AAI) presents almost exclusively with telogen hairs.<sup>[10,14]</sup>

Dermoscopy has proven to be a useful tool for visualizing fine structures in scalp skin and hair fibers, especially for characterizing alopecia hair loss regions.<sup>[12,15]</sup> In comparison to trichograms, dermoscopy has the advantage of better visualization of surface structures and pigmentation of shed hair roots. The procedure is also non-invasive and easy to perform.<sup>[16]</sup> Dermoscopy equipment and related methodologies continue to be developed and may provide automated systems of dermatological diagnosis and experimental measurement.<sup>[17,18]</sup> The hair of Chinese ethnic groups makes a good sample population to study and easily discern full color

changes from black, to slightly decreased pigmentation, to fully depigmented hair shafts.

We hypothesized that, as hair root structures reflect hair follicle growth cycle stages, we might observe distinct hair root morphology associated with DAA. Hair root pigmentation changes could also reflect the pattern of hair loss, and may be distinctive between DAA and other forms of AA and TE. We anticipated that hair root structural changes can be observed with repeated sampling over time and could be used to determine disease progression in DAA from early, highly active inflammatory events through to a chronic disease phase. Therefore, this study was designed to investigate the presentation of hair roots of shed hairs and hair shafts *in situ*, in DAA. We revealed that there is a sequential cyclic change in the shed hair roots from the patients with DAA, as a consequence of anagen, catagen and telogen hair follicle transition.

## **2. Material and methods**

The present study was approved by the hospital ethics committee (Ethics No. [2012]021). A total of 23 patients with DAA were recruited from March 2014 to March 2015 in the Department of Dermatology, First Affiliated Hospital of Sun Yat-sen University. A total of 30 age-matched patients with PAA, 31 patients with ATE, and 24 individuals who did not have any hair loss (PT), were enrolled as the control groups. Clinical data collected included age, gender, clinical presentation, duration of disease and hair-pull test results.

Diagnosis of DAA was made when patients presented with sudden and diffuse hair loss, with or without characteristic patches of alopecia; with a strongly positive pull test; histopathology exhibiting typical features of AA. The area of hair loss was evaluated using the SALT score method.<sup>[19]</sup> Diagnosis of ATE criteria included acute onset of diffuse hair loss; weak positive pull test; a preceding cause such as high fever, crash-diet, etc.; and exclusion of other diseases associated with sudden hair loss.

Hair root samples (50-100 hairs per sample) were collected with a light pull without force in the pull test at every visit, or by patients after hair washing, and examined by hand-held non-contact polarized dermoscopes (Dermlite, DL3 and DL2 models, 3Gen, San Juan Capistrano, CA, USA). For PAA, samples were taken from the peripheral zone of hair loss lesions where active disease would be expected. Scalp hair-loss regions were also examined by dermoscopy. A scalp biopsy and routine histopathology analysis was performed on a subset of patients.

Collected data was analyzed by SPSS version 17.0. Continuous variables were analyzed by Student's t-test, and categorical variables were analyzed by Chi-Square or Fisher's exact test. Univariate analysis was performed using Fisher's exact test and Wilcoxon rank sum test. Associations between two variables were analyzed using Spearman rank correlation test. A one-tailed p-value of <0.05 was considered statistically significant.

### **3. Results**

#### **3.1. Clinical data**

In the group of 23 patients with DAA, all patients were female, age 15 to 57 years, an average age of 30.1 years (Table S1). Most of the patients (21/23, 91.3%) came to our hair loss clinic between March and September. Only six patients (6/23, 26.1%) first developed patchy hair loss prior to the diffuse hair loss onset events. Twelve patients came to our clinic between 3 to 14 weeks after initial hair loss event and were followed up 3-17 times during the disease episode, among them, 5 patients (5/12, 41.7%) were observed with total hair loss.

In the group of 30 patients with PAA, only longer disease duration and larger hair loss areas were found significantly different in PAA ( $P<0.05$ ). In the group of 31 patients with ATE, all but one was female, with an average 30.7 years of age. In the group of 24 normal controls, all but two were female, average age was 25.7 years.

## **3.2. Morphology of hair roots**

### **3.2.1. *Hair roots in normal controls***

Hair roots from normal controls (physiological telogen/exogen, PT), collected by hair pulling or combing, showed both telogen (T) with a typical club shape (Figure S1A,B) and exogen (E) with a smaller and narrowed club shape and usually less pigmentation (Figure S1D). The ratio of T to E was 1:0.3. The club of a typical telogen root was seen in dermoscopy as a semi-transparent bulge, with an intense pigment ring in the middle part. Sometimes a totally pigmented (Figure S1B) or totally non-pigmented club could be seen (Figure S1C).

### ***3.2.2. Hair roots of ATE patients***

Hair roots from patients with ATE collected by positive hair pull test displayed both typical telogen roots with decreased pigmentation (Figure S1D) and exogen morphology, also with decreased pigmentation (Figure S1E). The ratio of T:E at 1:2.3 was significantly lower than that of normal controls (1:0.3,  $P<0.001$ ) (Table 1).

### ***3.2.3. Hair roots of DAA and PAA patients***

Hair roots collected from patients with active DAA or PAA by positive hair pull test exhibited varied features including; 1) pigmented pencil point-like anagen hair roots (Figure S1F); 2) blunt brush-like hair roots, resulting from broken hair (Figure S1G); 3) pointed or irregular unpigmented cornified catagen roots (Figure S1H,I); 4) fully developed club hair roots (Figure S1J).

### ***3.2.4. Comparison of hair roots among DAA, PAA, ATE patients and normal controls***

Uniform morphology of telogen/exogen could be seen in the hair roots collected from the same individuals with PT or ATE (Figure S2A,B). In PAA and DAA, both uniform anagen hair root morphology (Figure S2C), and mixed anagen, catagen and telogen hair root types could be observed (Figure S2D,E). Loss or decreased pigmentation in hair shafts of shed hairs was found in both DAA and PAA patients.

A higher percentage of anagen roots at first visit to the dermatology clinic was found in PAA patients (37.8%) in comparison with DAA patients' first visit, for an

average within all patients (21.3%,  $P<0.05$ ), which in-turn was higher than that observed with all visits (10.1%,  $P<0.05$ ) indicating a general decrease in anagen hair root frequency with time since first clinic attendance. A decreased ratio of telogen to exogen roots was found in patients with all types of AA compared to both normal controls and patients with ATE ( $P<0.001$ ). A ratio of telogen:exogen at 1:4.5 and 1:7.6 was found in hair roots from DAA patients at first visit or all consultations, respectively, significantly lower than that at 1:1.6 in patients with PAA ( $P<0.001$ ). Interestingly, patients with ATE had a lower ratio of telogen:exogen at 1:2.3 than that of PAA ( $P<0.001$ ).

Loss or decreased pigmentation in hair shafts of shed hairs was found in both DAA (Figure S2F) and PAA patients at the same distance of 1.1mm in their first consultation, but became longer in patients with DAA at all visits ( $P<0.05$ ), i.e., the length of depigmented hair shaft increased with disease duration time.

### **3.3. Dynamic changes in hair roots in DAA**

#### **3.3.1. *Sequential cyclic transitions of hair roots in DAA patients***

Hair samples from DAA patients were compared by aligning the samples by time since first reported onset of hair loss. We found anagen hair roots in early stage DAA in 18 patients (18/23, 78.3%) as the initial event, i.e., within the first 4-8 weeks of hair loss onset. There was a distinct transition from anagen to catagen, and then telogen in hair roots (Figure 1). Data of hair roots from all patients (Figure 2A), as well as that from 3 patients with typical transition over time (Figure 2B) is shown. Percentages of

hair cycle types throughout the whole time course is shown from 12 patients with comparatively complete disease duration data (Figure 2C). Over half of patients with anagen effluvium had a hair loss history of 2-8 weeks (10/18, 55.6%); most were around 4 weeks. Afterwards, a brief catagen effluvium followed and lasted for around 2 to 4 weeks. It was then followed by telogen effluvium for around 3-4 months. Anagen effluvium ended before half of the scalp hairs were shed in 11 patients (11/12, 91.7%) (Figure S3A). No difference was found in the transition of hair roots and disease course between patients with or without initial patchy hair loss.

In contrast, in ATE and normal controls, telogen/exogen hair root morphology remained throughout the course of hair loss, although color of the proximal shaft slightly decreased in ATE.

### ***3.3.2. Depigmentation of hair shafts in DAA patients***

Depigmentation of hair shafts in proximal hair roots was observed in all patients with DAA, and only in catagen and telogen/exogen roots at the later stage of the hair loss process. The length of depigmented hair shaft, as measured from the base of the plucked hair, increased with time of DAA disease duration ( $P < 0.001$ ,  $R = 0.739$ ), as shown by data from 3 patients with similar disease time frames (Figure S3B), with the longest depigmented length measuring close to 6mm; approximately 20 days of hair shaft growth/elongation. Interestingly, in one patient in the recovery phase with a few remaining long hairs, we found white segments in the middle of black hair shafts (Figure S2F).

### **3.4. Scalp dermoscopy**

#### **3.4.1. Scalp dermoscopic signs of DAA and ATE patients**

Black dots, loss of pigmentation in the proximal hair shafts, yellow dots, inconsistent hair shaft diameter/exclamation point hairs, broken hairs, and increased vellus hairs, were the main dermoscopic findings in patients with DAA (Figure S4A-C) or PAA (Figure S4D) similar to previous observations.<sup>[20]</sup> Broken hairs were seen with exogen roots (Figure S4C). Black dots and yellow dots were observed mainly in the early disease stage, broken hairs and depigmentation of proximal hair shafts were found in both early and late stage disease, whereas newly grown vellus hairs were more prominent in the late stage (Table S2). In ATE, apart from increased newly grown vellus hairs, slightly decreased pigmentation was found in a part of hair shafts close to the skin surface in the early disease stage (Figure S4E) or longer in the later stages (Figure S4F) in all patients in the ATE group.

#### **3.4.2. Correlation of scalp dermoscopic signs to morphology of hair roots**

In the first consultation of patients with DAA or PAA, black dots and exclamation mark hairs were found more commonly associated with hair pull tests exhibiting greater than 80% anagen hair roots, as compared to patients with catagen/telogen only hair roots (Table S2), but no significant differences were found ( $P>0.05$ ). Newly grown hairs were least frequent in the early stage and depigmented hair shafts were the most frequent feature observed in the later stage ( $P_s<0.01$ ). In the early stage,

black dots, exclamation mark hairs and variations in hair shaft thickness were found more often than in the later stage ( $P_s < 0.01$ ). Changes through the disease course in global views, hair roots and scalp dermoscopy data are shown for one patient (Figure 3).

### **3.5. Histopathologic features**

#### **3.5.1. *PT control subjects***

Club roots of shed hairs from normal individuals are fully cornified epithelium formed from hair matrix epithelial cells located in and above the bulb region in anagen phase follicles. The cells become cornified in the catagen phase to become a presumptive club; they can be observed as a uniform red-stained trichilemmal keratin sac in hematoxylin and eosin stained sections. The telogen hair root forms in the middle of the trichilemmal keratin sac. The pigment ring seen in the middle part of a club root from PT probably reflects the pigmented section in the hair matrix (Figure 4A,B). The depigmented proximal end of club hairs from PT was likely formed by epithelial matrix cells originally surrounding the dermal papilla, below the level of pigmented matrix.

#### **3.5.2. *DAA patients***

A histopathologic study was carried out in 9 of the 23 patients with DAA (Table S3). Among them, 4 patients were at an early disease stage with anagen hair roots (group 1) and 5 patients were at a later stage with catagen/telogen hair roots (group 2).

In group 1, more anagen roots and fewer telogen roots were found than group 2 ( $P < 0.05$ ). Prominent inflammatory cell infiltration with eosinophils and/or plasma cells in a “swarm-of-bees-like” infiltration around the bulb area were seen in all four patients in group 1 (Figure 4E), more frequent than that found in group 2 at the later stage ( $P_s < 0.01$ ) where no intense inflammatory cell infiltration was seen (Figure 4F). In the early stages, prominent apoptosis in the ORS, trichomalacia, pigment casts (Figure 4D), and pigment incontinence in the bulb area, were frequently observed. Follicles in anagen could be found in close vicinity to catagen stage follicles (Figure 4C). In contrast in group 2, more miniaturized follicles were found (Figure 4F). Upper follicle damage at the peripheral ORS and at the isthmus level was seen in both early and later stage patients.

#### **4. Discussion**

To our knowledge this study is the first to examine DAA progression over a time course with statistical analysis. We found anagen and depigmented catagen/telogen roots in both PAA and DAA. Importantly, over time, a dynamic transition of anagen to catagen and finally to telogen stage hair roots and follicles was found in patients with DAA. Previously, both anagen and telogen hair roots were found in patients with DAA,<sup>[21]</sup> although it was suggested that anagen hairs were shed only in patchy AA and not in patients with DAA.<sup>[22]</sup> In contrast, our observations and statistical analyses here indicate acute DAA is primarily achieved through an anagen effluvium. Previous studies may be based on clinical data only at a specific time point in the disease cycle,

missing out the whole picture. Rebora suggested that dystrophic anagen in DAA may be dependent on the timing of clinical observation and is followed by a telogen effluvium.<sup>[21]</sup> We were able to see patients with hair loss from an early disease stage onwards mostly due to the walk-in consultation setting of tertiary hospitals in China and confirm a change from predominantly anagen effluvium to telogen effluvium in DAA over time. These phase specific features are summarized (Table S4).

Previously, Whiting et al suggested the degree of inflammation around follicles could determine whether anagen or telogen effluvium was observed in AA and that inflammation and effluvium patterns changed over time.<sup>[23,24]</sup> Here, we provide supporting evidence that both anagen and telogen effluvium can be observed in the same (DAA) subject, depending on the timing of the observation point. Eckert et al, examined hair roots from PAA, using templates to define distance from the center of individual AA patches.<sup>[25]</sup> They suggested AA most commonly begins with telogen effluvium (as exemplified by telogen club hairs) followed by dystrophic anagen; they also indicate direct progression to dystrophic anagen is possible. Our data indicates anagen effluvium is the initial event in DAA onset. This suggests a severe insult occurs to affected hair follicles in acute DAA, as supported by our histological observations of intense follicular inflammation.

Disruption in the anagen phase results in impaired mitotic or metabolic activity, with hair fibers subsequently broken off above the matrix level and shed as anagen roots with pencil point or blunt brush shapes. The sequential transition of shed hairs from anagen to catagen/telogen we found here in patients with DAA is similar to

guinea pigs receiving irradiation.<sup>[21]</sup> Anagen effluvium can happen in AA as the attack on hair follicles induces shedding as anagen roots.<sup>[26,27]</sup> Catagen effluvium has not been reported before in AA, but judging from the morphology of the hair roots, we perceived a transient catagen release lasting around 4 weeks in the middle of hair loss process. Drug induced hair loss can involve both anagen and telogen effluvium,<sup>[28]</sup> but it is unclear whether the same transition from anagen to catagen and to telogen exists.

In this study, telogen effluvium in DAA was found to be different from that in ATE, in that loss of pigment in proximal hair shafts was much more prominent in DAA. Melanocytes could be significant in AA pathogenesis and hair pigmentation may reflect their activity.<sup>[29,30]</sup> Slight pigmentation disturbance was found in this study to exist in ATE before the end of the anagen stage, possibly due to termination of melanogenesis shortly prior to cessation of anagen. Immediate anagen release, delayed anagen release, immediate telogen release, short anagen syndrome and delayed telogen release have been proposed to be the mechanisms of TE by Headington,<sup>[31]</sup> and premature teloptosis, collective teloptosis and premature entry into telogen as described by Rebora.<sup>[8]</sup> The pathogenic mechanism of ATE in this study is considered to be immediate anagen release or premature entry into telogen. We also found increase of exogen in both ATE and DAA. We speculate in both conditions, rather than shedding after telogen, as in the normal physiological condition termed teloptosis,<sup>[8,32]</sup> exogen may occur during immature telogen, released earlier than it should be; an illustration of the shortened telogen phase.

We propose two possible mechanisms to explain this sequential cyclic transition

of hair roots in DAA. Firstly, the insult is cycle-specific, i.e., hair follicles have varied vulnerability to an insult due to the different cyclic stages they are in. Follicles in early anagen may be affected the most and shed as anagen hairs, but follicles in late anagen or pre-catagen at the time of insult may accelerate into catagen or telogen and shed as such, similar to that in irradiation induced hair loss proposed by Rebora.<sup>[21]</sup> Secondly, varied severity of the inflammatory insult over the whole scalp, or multifocal insults, may lead to devastating hair bulb and IRS disruption resulting in anagen effluvium in some places, but catagen/telogen effluvium elsewhere.

Pigmentation of hair shafts takes place in anagen; the cessation of it has been used as a marker for the end of the anagen phase in the normal hair cycle.<sup>[33,34]</sup> Due to the full color range observed from black hairs of Chinese ethnic individuals, we found in DAA that depigmentation occurred early and lasted for the whole disease process, and some follicles can even survive. Therefore, disturbance in pigment production does not necessarily correlate with anagen stage arrest of hair fiber production in the situation of DAA.

Studies of hair roots commonly use those obtained from wash tests, but we used mainly hair roots from pull tests in this study. We found it is similar to wash tests with few artifacts, although pull tests may not be as representative of the whole scalp. Trichograms have been commonly used in the past to examine hair roots, but this requires a bench top microscope. Also, it is difficult to visualize decreased pigmentation of hair roots, although trichograms can more easily identify internal structures such as hair shaft medullas. Dermoscopy, however, is easily available in

most clinics and readily reveals any subtle changes of pigmentation and outside contours of hair shafts and hair roots. It can be used to examine both hair roots and scalp conditions, to provide us with missing pieces in the information jigsaw puzzle, where the status of hair follicles and hair roots are closely interlocked.

## **5. Conclusion**

In conclusion, we found a characteristic sequential cyclic staging of shed hairs in patients with DAA which may be useful for disease staging in the dermatology clinic. For experimental research, the data shows the predominant hair root morphology from the same DAA patients changed over time, from anagen initially, through catagen to telogen. As hair fiber morphology reflects hair follicle growth cycle patterns, significant variability in the histopathology and inflammatory marker patterns should be expected from different DAA patients depending on the time point at which the biopsy is collected through the course of the disease. Detailed staging of the AA disease will be required to improve the consistency of data from patients in different clinical categories.

## **Acknowledgements**

This study was supported by the following grants to Xingqi Zhang: National Natural Science Foundation of China (81573066); Natural Science Foundation of Guangdong Province (2014A030313098).

## References

- [1] K. J. McElwee, A. Gilhar, D. J. Tobin, Y. Ramot, J. P. Sundberg, M. Nakamura, M. Bertolini, S. Inui, Y. Tokura, L. E. King, Jr., B. Duque-Estrada, A. Tosti, A. Keren, S. Itami, Y. Shoenfeld, A. Zlotogorski, R. Paus. *Exp Dermatol.* **2013**, *22*, 609.
- [2] K. J. McElwee, D. J. Tobin, J. C. Bystryn, L. E. King, Jr., J. P. Sundberg. *Exp Dermatol.* **1999**, *8*, 371.
- [3] E. J. Van Scott. *J Invest Dermatol.* **1958**, *31*, 35.
- [4] S. F. Li, X. T. Zhang, S. L. Qi, Y. T. Ye, H. Cao, Y. Q. Yang, K. J. McElwee, X. Zhang. *Clin Exp Dermatol.* **2015**, *40*, 171.
- [5] B. Zhang, Y. Zhao, Z. Cai, S. Caulloo, K. J. McElwee, Y. Li, X. Chen, M. Yu, J. Yang, W. Chen, X. Tang, X. Zhang. *Australas J Dermatol.* **2013**, *54*, 184.
- [6] H. J. Choi, C. W. Ihm. *Acta Dermatovenerol Alp Pannonica Adriat.* **2006**, *15*, 27.
- [7] Y. Zhao, B. Zhang, S. Caulloo, X. Chen, Y. Li, X. Zhang. *Indian J Dermatol Venereol Leprol.* **2012**, *78*, 709.
- [8] A. Rebora. *G Ital Dermatol Venereol.* **2014**, *149*, 47.
- [9] F. Torres, A. Tosti. *Semin Cutan Med Surg.* **2015**, *34*, 67.
- [10] A. Rebora. *Dermatologica.* **1987**, *174*, 214.
- [11] R. Quercetani, A. E. Rebora, M. C. Fedi, G. Carelli, S. Mei, A. Chelli, E. Poli. *J Eur Acad Dermatol Venereol.* **2011**, *25*, 808.
- [12] S. Inui, T. Nakajima, S. Itami. *Dermatology.* **2008**, *217*, 333.
- [13] L. Molina, A. Donati, N. S. Valente, R. Romiti. *Clinics (Sao Paulo).* **2011**, *66*, 513.
- [14] M. Sato-Kawamura, S. Aiba, H. Tagami. *Dermatology.* **2002**, *205*, 367.
- [15] A. Tosti, D. Whiting, M. Iorizzo, M. Pazzaglia, C. Misciali, C. Vincenzi, G. Micali. *J Am Acad Dermatol.* **2008**, *59*, 64.
- [16] F. Lacarrubba, G. Micali, A. Tosti. *Curr Probl Dermatol.* **2015**, *47*, 21.
- [17] D. S. Gareau, J. Correa da Rosa, S. Yagerman, J. A. Carucci, N. Gulati, F. Hueto, J. L. DeFazio, M. Suarez-Farinas, A. Marghoob, J. G. Krueger. *Exp Dermatol.* **2017**, *26*, 615.
- [18] S. Ud-Din, A. Bayat. *Exp Dermatol.* **2016**, *25*, 579.
- [19] E. A. Olsen. *Dermatol Ther.* **2011**, *24*, 311.
- [20] M. Miteva, C. Misciali, P. A. Fanti, A. Tosti. *J Cutan Pathol.* **2012**, *39*, 596.
- [21] A. Rebora. *Dermatology.* **2003**, *207*, 339; author reply 340.
- [22] A. Rebora. *Clinics (Sao Paulo).* **2011**, *66*, 1481.
- [23] L. C. Dy, D. A. Whiting. *Dermatol Ther.* **2011**, *24*, 369.
- [24] D. A. Whiting. *Arch Dermatol.* **2003**, *139*, 1555.
- [25] J. Eckert, R. E. Church, F. J. Ebling. *Br J Dermatol.* **1968**, *80*, 203.
- [26] A. J. Kanwar, T. Narang. *Indian J Dermatol Venereol Leprol.* **2013**, *79*, 604.
- [27] T. Karashima, D. Tsuruta, T. Hamada, N. Ishii, F. Ono, A. Ueda, T. Abe, T. Nakama, T. Dainichi, T. Hashimoto. *J Dermatol.* **2013**, *40*, 1045.
- [28] R. M. Trueb. *Dermatology.* **2007**, *215*, 1.
- [29] M. Zheng, Y. Ren. *Exp Dermatol.* **2017**, *26*, 542.
- [30] K. J. McElwee, K. Silva, W. G. Beamer, L. E. King, Jr., J. P. Sundberg. *Exp Dermatol.* **2001**, *10*, 420.
- [31] J. T. Headington. *Arch Dermatol.* **1993**, *129*, 356.

- [32] C. Pierard-Franchimont, G. E. Pierard. *Dermatology*. **2001**, 203, 115.
- [33] K. S. Stenn, R. Paus. *Physiol Rev*. **2001**, 81, 449.
- [34] D. J. Tobin. *Pigment Cell Melanoma Res*. **2010**, 24, 75.


## Tables

Table 1. Percentage of cyclic type of hair roots from patients and normal controls.

	DAA		PAA	ATE	PT
	1 <sup>st</sup> visit	All visits			
No. individuals	23	23	30	31	24
Anagen (%)	21.3±6.5*	10.1±2.6 <sup>#</sup>	37.8±5.3 <sup>&amp;</sup>	-	-
Catagen (%)	24.4±3.5	25.7±2.9	22.1±3.1	-	-
Telogen & exogen (%)	54.9±6.4*	63.8±3.8 <sup>#</sup>	40.0±5.5	100	100
Telogen:exogen	1:7.6 <sup>***</sup>	1:4.5 <sup>###</sup>	1:1.6 <sup>&amp;&amp;&amp;</sup>	1:2.3	1:0.3
Length of depigmented hair shaft (mm)	1.1±0.6*	1.5±0.5 <sup>#</sup>	1.1±0.8	-	-

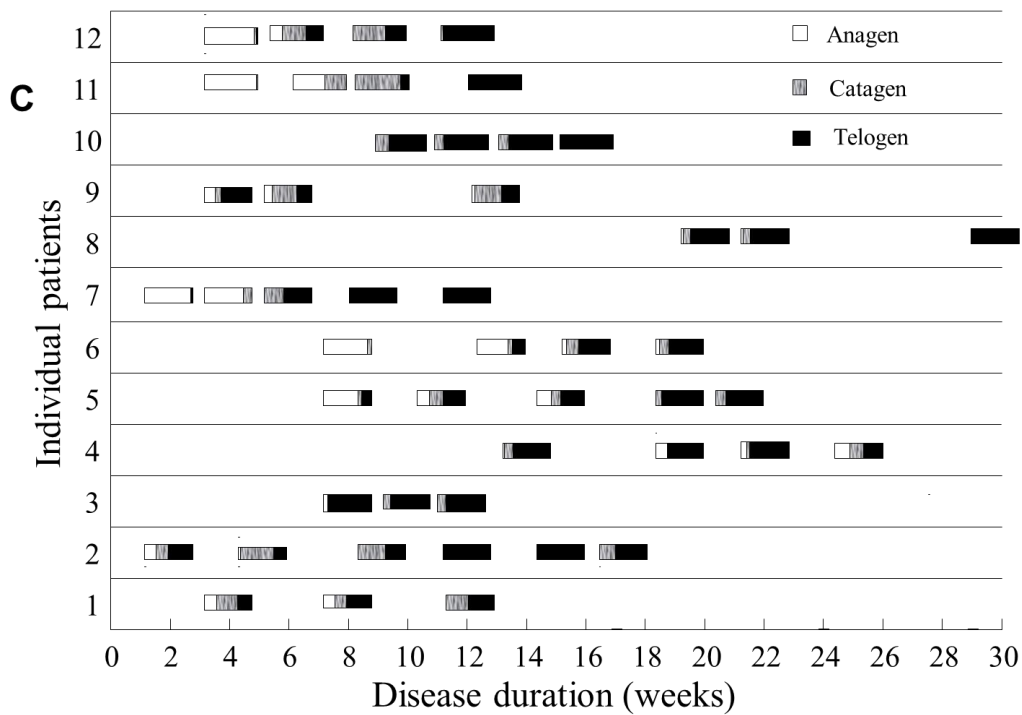
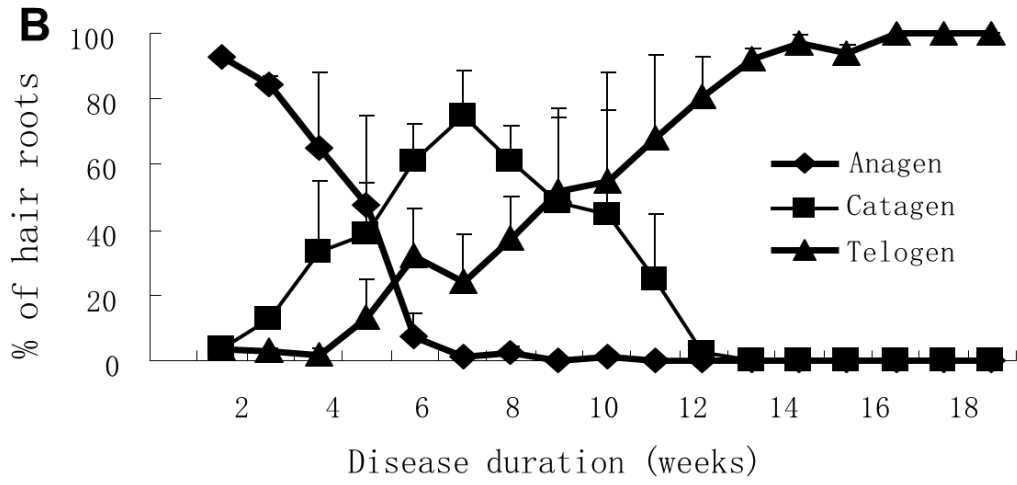
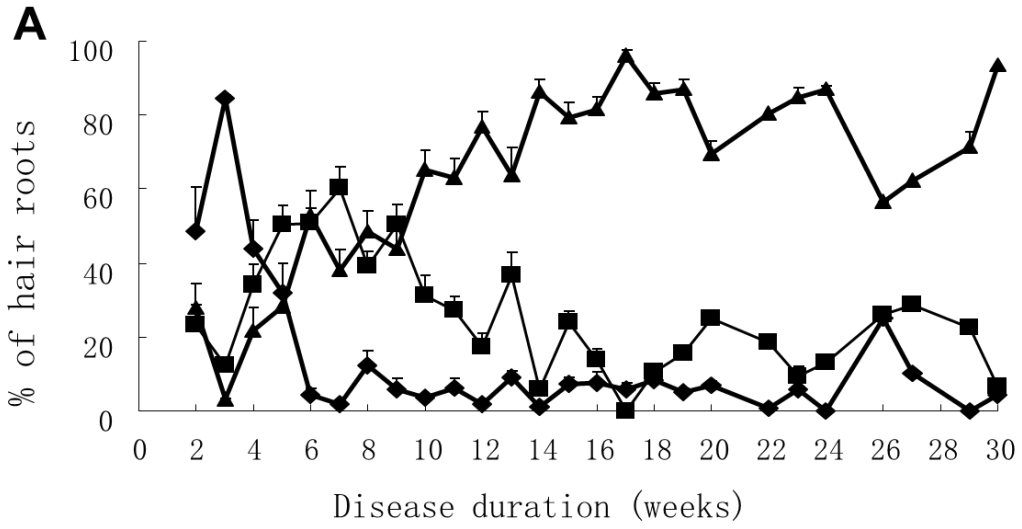
Note: 1. Comparison was made among DAA and PAA only,  $P < 0.05$ : \* and #, # and &, \* and &;  $P < 0.001$ : \*\*\* and ###, ### and &&&, \*\*\* and &&&. 2. T:E of both ATE and PT were all significantly higher than that in DAA, and higher in PT than that in PAA, but in ATE, it was lower than that of PAA ( $P_s=0$ ).

## Figures




**Figure 1. Sequential cyclic transition of hair roots in patients with DAA.**

Hair roots from a patient with DAA showed distinct cyclic transition from anagen to catagen and then to telogen/exogen over time.



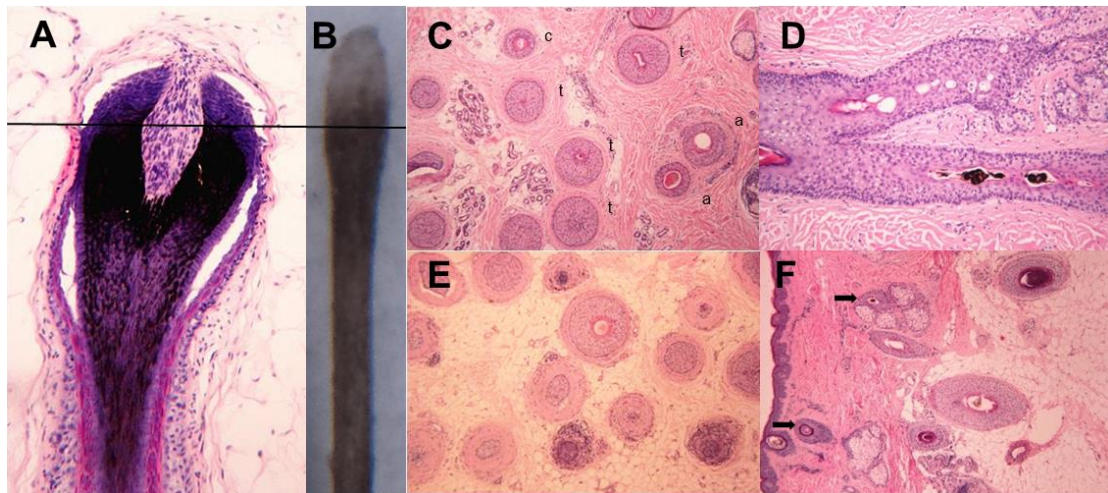
**Figure 2. Percentages of hair roots in anagen, catagen and telogen hair cycle stages throughout the disease duration of DAA.**

A: Changes in the percentage of anagen, catagen, and telogen hairs are shown for 12 patients with comparatively complete hair pull test data as evaluated over time / disease duration since first onset of DAA. B: Data from 3 patients who came to the hair clinic very early after initial development of DAA at 2-3 weeks after first onset and with similar timeframes of their cyclic transition from anagen, through catagen, to telogen. C: Percentage of hair roots in hair cycle states throughout the disease duration in 12 patients, who are the same as in 2A, each shown individually.



**Fig. 3. Concomitant global view of scalp and dermoscopy of hair roots and scalp of a patient with DAA.**

Concomitant global views of scalp hair, hair roots and scalp dermoscopy from a patient throughout the disease duration are shown here.



**Fig. 4. Histopathologic features of hair follicles in normal controls, early and later stage DAA.**

A and B: Anagen follicle and club root of a shed telogen hair from a normal individual. The cornified club is formed from hair matrix epithelial cells just above the bulb region. The pigment ring in the middle part of a club root reflects the pigmented section in the matrix in hair bulb. The depigmented proximal end of the club is probably formed by the epithelial matrix cells surrounding the dermal papilla, below the level of pigmented matrix at the time of anagen cessation. C-E: Early stage DAA. C: Follicular regression was prominent, anagen (a) can be seen in close vicinity to catagen (c) and telogen (t). D: Prominent apoptosis in ORS, trichomalacia and pigment casts can be seen. E: Prominent inflammatory infiltration existed surrounding the bulbar area. F: Later stage DAA. Less inflammatory infiltration was observed at this stage. Miniaturized follicles could be seen (arrow) among terminal anagen follicles.



(%)								
Number of cases	4	14	5	<b>23</b>	4	20	4	<b>28</b>
Yellow dots	3 (75.0)	13 (92.3)	4 (80.0)	<b>20(87.0)</b>	4 (100)	14 (70.0)	2 (50.0)	<b>20(71.4)</b>
Black dots	4 (100)	10 (71.4)	2 (40.0)	<b>16(69.6)</b>	4 (100)	17 (87.0)	0	<b>21(75.0)</b>
Exclamation mark hairs	4 (100)	10 (71.4)	3 (60.0)	<b>17(73.9)</b>	4 (100)	19 (95.0)	0	<b>23(82.1)</b>
Broken hairs	4 (100)	11 (78.6)	4 (80.0) *	<b>19(82.6)</b>	4 (100)	19 (95.0)	0#	<b>23(82.1)</b>
Uneven thickness of hair shaft	3 (75.0)	9 (64.3)*	2 (40.0)	<b>14(60.9)</b>	4 (100)	19 (95.0)#	0	<b>23(82.1)</b>
Depigmented hair shaft	4 (100)	14 (100)	5 (100)	<b>19(82.6)</b>	4 (100)	19 (95.0)	3 (75.0)	<b>26(92.9)</b>
Newly grown hairs	0	9 (64.3)	2 (40.0)	<b>11(47.8)</b>	1 (25.0)	16 (80.0)	4 (100)	<b>21(75.0)</b>
<b>Hair roots</b>	<b>Early stage of DAA</b>				<b>Late stage of DAA</b>			
	<b>Scalp dermoscopy, N (%)</b>	<b>A&gt;80%</b>	<b>A/C/T</b>	<b>C/T</b>	<b>Total</b>	<b>A&gt;80%</b>	<b>A/C/T</b>	<b>C/T</b>
Number of visits	6	16	2	<b>24</b>	0	10	20	<b>30</b>
Depigmented hair shaft	6 (100)	16 (100)	2 (100)	<b>24(100)</b>	0	10 (100)	20 (100)	<b>30(100)&amp;</b>
Yellow dots	4 (66.7)	14 (87.5)	0	<b>18(75.0)</b>	0	8 (80.0)	12 (60.0)	<b>20(66.7)</b>
Black dots	6 (100)	16 (100)*	2 (100)	<b>24(100)</b>	0	4 (40.0)#	10 (50.0)	<b>14(46.7)</b>
Exclamation mark hairs	6 (100)	16 (100)*	2 (100)	<b>24(100)</b>	0	7 (70.0)#	13 (65.0)	<b>20(66.7)</b>
Broken hairs	4 (66.7)	16 (100)	0	<b>20(83.3)</b>	0	10 (100)	13 (65.0)	<b>23(76.7)</b>
Uneven thickness of hair shaft	6 (100)	16 (100)*	2 (100)	<b>24(100)</b>	0	6 (60.0)#	8 (40.0)	<b>14(46.7)</b>
Newly grown hairs	0	7 (43.8)*	1 (50.0)	<b>8(33.3)&amp;</b>	0	6 (60.0)	18 (90.0)	<b>24(80.0)</b>

Note: 1. P<0.05: \* and #. 2. &: the most or least frequency among the row of Totals.

A: anagen, C: catagen, T: telogen.

Table S3 (supplemental). Pathological features of hair loss regions in DAA patients

	<b>Group 1</b>	<b>Group 2</b>
<b>Number of cases</b>	4	5
<b>Hair pull test predominant hair root presentation</b>	Anagen effluvium	Catagen/telogen effluvium
<b>Disease duration (weeks) at time of biopsy collection</b>	4.5±1.3	12.4±3.7
<b>% of A/C/T in hair roots in shed hairs at time of biopsy collection (average)*</b>	58.5/22.0/19.5	4.5/31.3/66.2
<b>Pathological stage</b>	Sub-acute	Chronic/recovery
<b>Terminal: vellus ratio*</b>	11:1	5:1
<b>Hair follicles in A: C/T ratio*</b>	11:19	5:1
<b>Mosaic of A and C/T (%)**</b>	4 (100.0)	0
<b>Miniaturized hair follicles observed (% of patients)*</b>	0	4 (80.0)
<b>Upper follicle damage (% of patients)</b>	2 (66.6)	4 (80.0)
<b>Cleavage/Separation between CTS and ORS (% of patients)</b>	3 (75.0)	1 (20.0)
<b>Trichomalacia/pigment cast present*</b>	3 (75.0)	1 (20.0)
<b>Swarm-of-bees infiltration in bulb area (% of all follicles)**</b>	4 (100.0)	0
<b>Eosinophils/plasma cell infiltration (% of patients)**</b>	4 (100.0)	0
<b>Pigment incontinence in bulb area (% of patients)</b>	2 (50.0)	0

\*P<0.05, \*\*P<0.01. A: anagen, C: catagen, T: telogen.


Table S4 (supplemental). Summary of common events in the early and late phases of

DAA

	<b>Early disease phase</b>	<b>Late disease phase</b>
<b>Predominant presentation of hair roots</b>	Anagen effluvium	Catagen and Telogen effluvium
<b>Time frame</b>	1 <sup>st</sup> month	2 <sup>nd</sup> month and 3 <sup>rd</sup> -4 <sup>th</sup> month
<b>Extent of hair loss</b>	Less than 50% hair loss	More than 50% hair loss or total hair loss

<b>Depigmentation of hair roots</b>	Mild; Not in anagen hair roots	Prominent and longer with disease course
<b>Scalp dermoscopy</b>	Black dots; exclamation mark hairs; inconsistent thickness of hair shafts	Broken hairs; depigmented proximal hair shafts
<b>Histopathology</b>	Increase of catagen stage follicles; cleavage between ORS and CTS; trichomalacia; prominent bulbar infiltration	Miniaturized follicles; follicular regrowth; mild or no infiltration


### Supplemental Figures



**Figure S1 (supplemental). Morphology of hair roots by dermoscopy.**

A-C: Telogen roots from normal controls were seen with a typical club shape, with pigmentation at typically half (A) or all (B) of the keratinized club or without pigmentation (C). D-E: Hair roots collected from patients with acute telogen effluvium (ATE) displayed both typical telogen roots with decreased pigmentation (D) and of exogenous morphology with a smaller and narrowed “baseball bat” shape and also

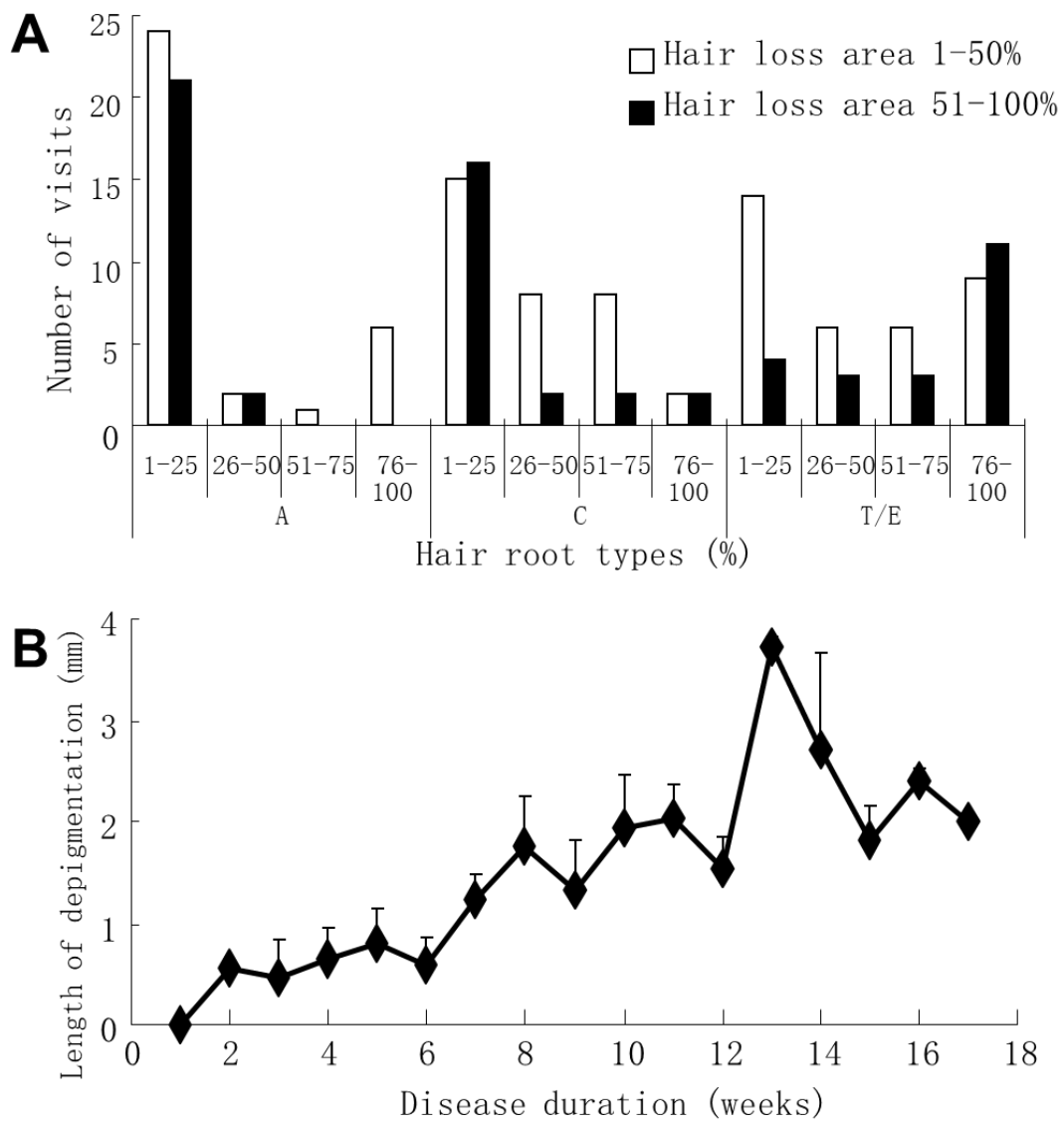
decreased pigmentation (E). F-J: Hair roots collected from patients with active DAA or PAA by positive hair pull test exhibited anagen roots, such as pigmented, pencil point-like, hair roots (F), blunt brush-like hair roots (G); catagen roots with pointed or irregular unpigmented cornified roots (H, I); and telogen/exogen roots, similar to those in patients with ATE, but with much decreased, or complete loss of, hair root pigmentation (J).



**Figure S2 (supplemental). Shed hairs from patients with DAA, PAA, ATE and controls.**

A and B: Hair roots collected from the same control individual exhibiting telogen

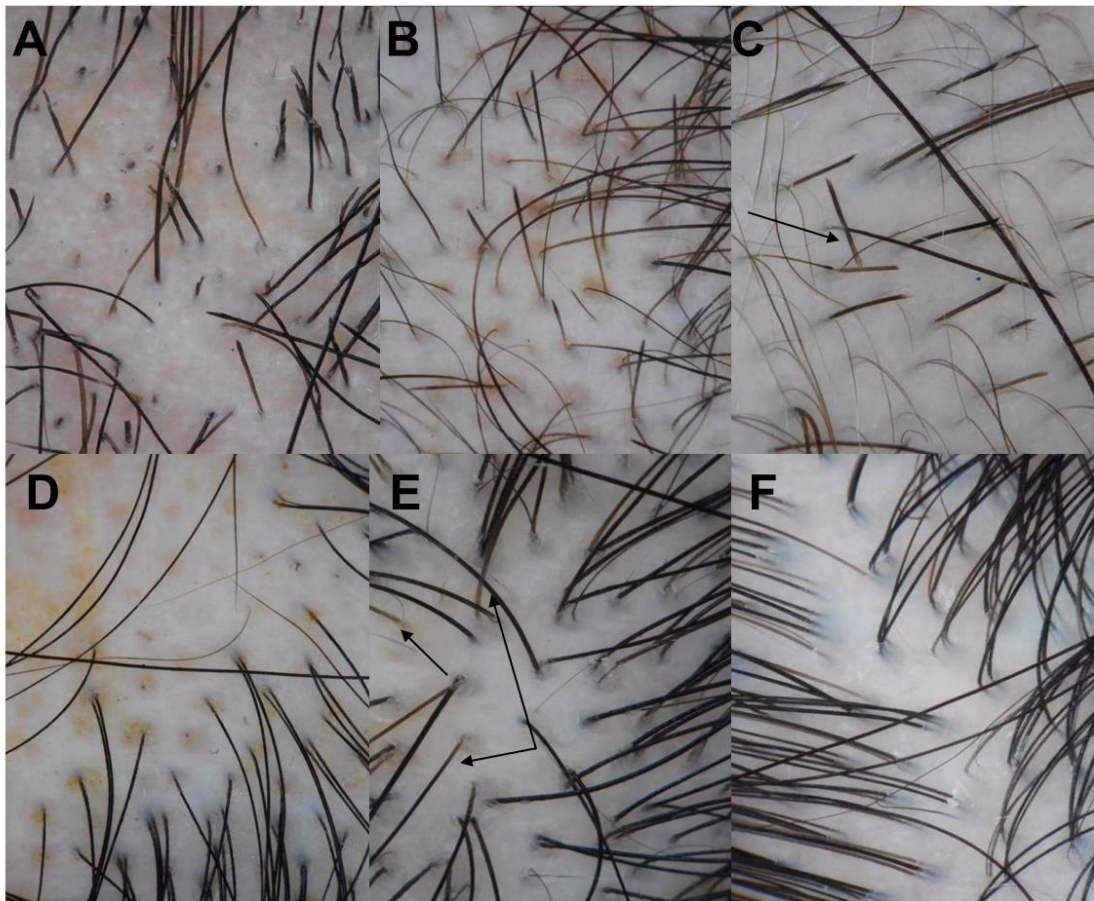
shape (A) and at the time with ATE exhibiting an exogen shape (B). C: Anagen roots from patients in the early phase of DAA. D and E: Mixed hair root types with anagen, catagen and telogen roots together were more frequently observed in PAA (D) and DAA (E) at later times after first onset of AA. F: Long hairs shed from one patient in the recovery phase of DAA showed depigmented segment in the middle part of hair shafts.



**Figure S3 (supplemental). Correlation of hair root cycle type to hair loss area,**

**and length of hair shaft depigmentation to disease duration.**

A: The correlation of the percentage of hair root cycle types and scalp hair loss area in patients was analysed. Anagen effluvium ended before half of scalp hair was shed, whereas catagen and telogen effluvium could occur in association with any hair loss area size. B: Hair shaft depigmentation in the proximal part of hair roots was observed in all patients with DAA, the length of depigmented hair shaft increased with days of disease duration in DAA, as shown by data from 3 patients ( $P<0.001$ ,  $R=0.739$ ).



**Figure S4 (supplemental). Scalp dermoscopy of patients with DAA.**

A-C: Black dots (A), yellow dots (B), uneven hair shaft diameters, exclamation point hairs (B), broken hairs (A, B, C), loss of proximal hair shaft pigmentation, and

increased vellus hairs, were the main dermoscopic findings in patients with DAA. Broken hairs (arrow) were seen with exogen roots (C). D: Yellow dots, black dots and increased vellus hairs were also seen in PAA. E and F: In ATE, apart from increased numbers of newly grown vellus hairs, slightly decreased pigmentation was found in the proximal part of hair shafts in early stage ATE (E, arrows). Whereas in later stage ATE, hair shafts with decreased pigmentation disappeared (F).