

bradscholars

A carbon and nitrogen isotopic investigation of a case of probable infantile scurvy (6th- 4th centuries BC, Slovenia)

Item Type	Article
Authors	Nicholls, Rebecca A.;Buckberry, Joanne;Beaumont, Julia;Črešnar, M.;Mason, P.;Koon, Hannah
Citation	Nicholls RA, Buckberry J, Beaumont J et al (2020) A carbon and nitrogen isotopic investigation of a case of probable infantile scurvy (6th- 4th centuries BC, Slovenia). Journal of Archaeological Science: Reports. 30: 102206.
DOI	https://doi.org/10.1016/j.jasrep.2020.102206
Rights	© 2020 Elsevier. Reproduced in accordance with the publisher's self-archiving policy. This manuscript version is made available under the CC-BY-NC-ND 4.0 license.
Download date	2026-04-12 13:16:43
Link to Item	https://bradscholars.brad.ac.uk/handle/10454/17626.2

A carbon and nitrogen isotopic investigation of a case of probable infantile scurvy (6th- 4th centuries BC, Slovenia)

Rebecca Nicholls¹, Jo Buckberry¹, Julia Beaumont¹, Matija Črešnar^{2,3}, Phil Mason³, Ian Armit⁴ and Hannah Koon^{1*}

¹ School of Archaeological and Forensic Sciences, University of Bradford, Bradford, West Yorkshire, BD7 1DP

² Department of Archaeology, University of Ljubljana, Aškerčeva 2, 1000 Ljubljana, Slovenia

³ Institute for the Protection of Cultural heritage of Slovenia, Poljanska 40, 1000 Ljubljana, Slovenia

⁴ Department of Archaeology, University of York, The King's Manor, York YO1 7EP

r.nicholls@student.bradford.ac.uk

j.buckberry@bradford.ac.uk

j.beaumont6@bradford.ac.uk

matija.cresnar@ff.uni-lj.si

phil.mason@zvkds.si

ian.armit@york.ac.uk

*h.koon@bradford.ac.uk

Abstract

This paper presents a case study of a young infant, from a larger isotopic and osteological investigation of Bronze/Iron Age (14th-4th century BC) skeletal assemblages from Croatia and Slovenia. The osteological analysis of this infant identified pathological lesions including abnormal porosity and new bone formation consistent with malnutrition and phases of recovery. The distribution and appearance of these pathological lesions (i.e. diffuse micro-porosities and plaques of subperiosteal new bone formation on the skull and long bones) led to the conclusion that this infant probably suffered from scurvy (vitamin C deficiency). The diet and nitrogen balance of this individual were investigated by incremental dentine sampling and stable carbon and nitrogen isotope analysis. This sampling method provided a high resolution record of dietary and metabolic changes from pre-birth to around the time of death. The resulting isotope data exhibited unusually high $\delta^{13}\text{C}$ values for this region and time period (between -11.3‰ and -12.6‰), while $\delta^{15}\text{N}$ values were observed to be c. 3‰ above that of rib collagen sampled from contemporary adults recovered from the same site. The isotope profiles generated from the incremental dentine analysis show that $\delta^{13}\text{C}$ and especially $\delta^{15}\text{N}$ continue to increase until death. The evidence from the skeletal remains and high resolution isotopic data support the hypothesis that this infant suffered from severe malnutrition and an increasingly negative nitrogen balance. The paper discusses some scenarios which could have resulted in these unusual isotope ratios, whilst considering the diagnosis of possible metabolic disease. The paper also addresses the need for context when interpreting isotopic results. The isotope data should not be viewed in isolation, but rather as part of a multidisciplinary approach, considering the multiple causes of isotopic variability.

Key words

Incremental dentine, nitrogen balance, pathology, vitamin C deficiency, breastfeeding, Early Iron Age

1. Introduction

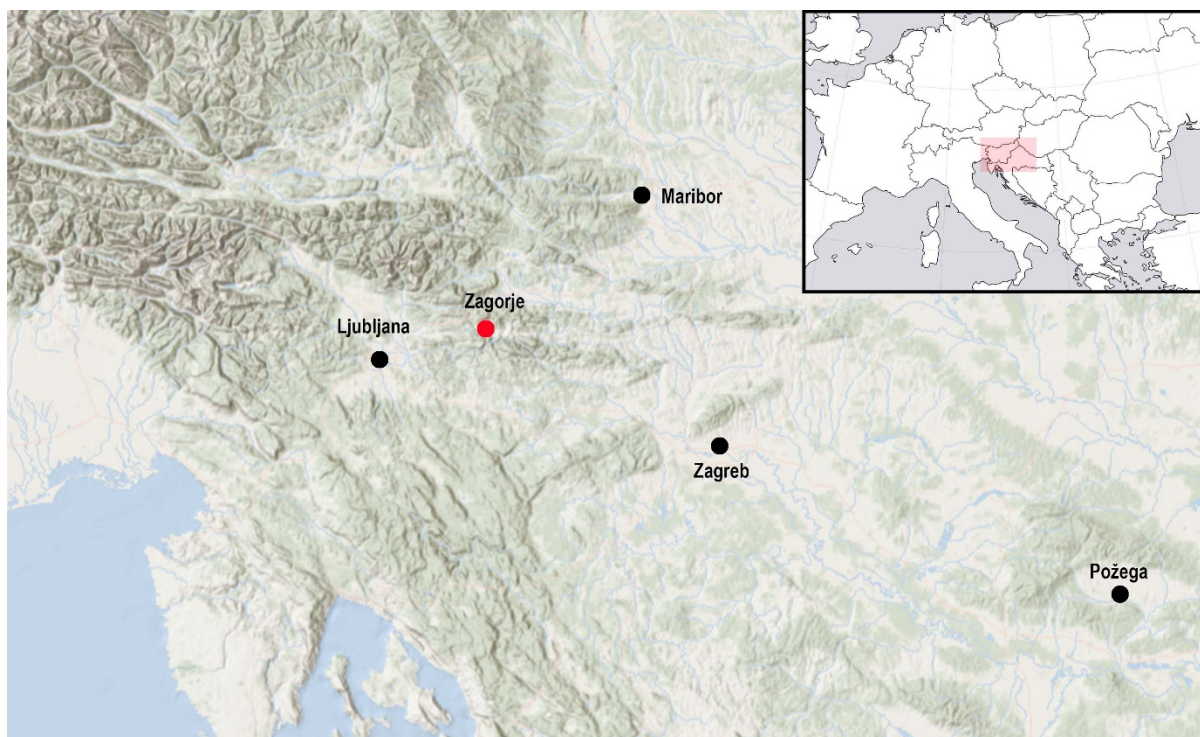


Figure 1. Map of south-eastern Europe with the site of Zagorje ob Savi marked in red (Sources: www.freeworldmap.net; www.esri.com).

This paper provides a case study combining contextual, osteological and isotopic data to produce a biography for a single individual buried at the Early Iron Age cemetery at *Zagorje ob Savi*, (46°8'7.84" N, 14°59'36.04" E) Slovenia (6th-4th centuries BC). The study was drawn from a larger osteological and stable isotope investigation of skeletal material recovered from central and eastern Slovenia, and northern Croatia (Nicholls 2017). The infant presented in this paper was exceptional in both their osteological and isotopic results.

1.1 *Zagorje ob Savi*

The Early Iron Age cemetery at *Zagorje ob Savi* (*Kidričeva cesta*) is located at the foot of the hill known as *Ocepkov hrib*, where the contemporary settlement is located. The location of this site is highlighted in Figure 1. It lies close to the *Medija* stream, a tributary of the *Sava*, one of the major rivers of the region. The site belongs to the *Dolenjska* Early Iron Age (Hallstatt) regional group, although it is located on the northern fringes of this group (Supplementary 1) and was active only in the Late Hallstatt period (6th-4th centuries BC), as was the case for a number of sites in this region.

The cemetery is unusual in containing flat inhumation graves, in a region where monumental burial mounds are much more common. It is one of fourteen such cemeteries in the broader region, which, where they can be dated, generally belong to the Late Hallstatt period. Most are located in the northern

part of the *Dolenjska* cultural group area, i.e. the *Posavsko hribovje* hill range, close to the *Sava* River (Gabrovec 1966; Dular, Tecco Hvala 2007; Draksler 2007).

The cemetery at *Zagorje ob Savi* has been known since the end of the 19th century, when several graves were found during construction work. Some contained high status artefacts, including a belt plate featuring a hunting scene; however, contextual information on these burials is scarce (Gabrovec 1966; Draksler 2007). Recent development-led excavations provided the first opportunity to acquire high quality data from this site. This work revealed nine graves, six of which yielded human skeletal remains, set in three distinct groups. The central group comprised five graves including one with the infant skeletal remains that forms the basis of this paper.

It is impossible to date all the graves individually, as some were disturbed or lacked any grave goods (e.g. grave 1 and 4). Nevertheless, those containing datable finds seem without exception to date to the Late Hallstatt Period (Draksler 2011; Murko 2011; Draksler and Murko 2020 in press). The most informative finds are a serpentine type fibula with a saddle-shaped bow and a disc from grave 8 (variant IVb after Tecco Hvala 2014), dating to the 6th century BC (Tecco Hvala 2014), and a Certosa type fibula, from grave 2 (variant XII after Teržan 1976), which is characteristic of the 4th century BC (Teržan 1976). Radiocarbon dates for two of the graves (the infant burial discussed here, i.e. grave 7 and grave 8, with the serpentine fibula) fall within the so-called Hallstatt plateau, between approx. 750 and 400 BC. The infant grave (SUERC-69421, 2412 ± 29 BP) is weighted to the 6th and 5th centuries BC (550-401 cal BC (80.8 %); OxCal v4.2.4), while grave 8 (SUERC-69422, 2499 ± 28 BC) is weighted to the 8th to 6th centuries BC (781-538 cal BC (95.4 %)); OxCal v4.2.4; although, as mentioned above, the 6th century fibula from this grave would suggest that it falls towards the end of this distribution.

1.2 Evidence of diet in Iron Age Slovenia

Iron Age Slovenia was inhabited by agricultural communities. Their diet probably consisted of domesticated plants and animals. Evidence of faunal remains obtained from large settlement centres, such as *Stična* and *Cvinger*, show a predominance of cattle, followed by caprine (sheep/goat) and pig (Dular and Tecco-Hvala 2007). Wild animals made up a relatively small proportion of faunal remains, the most common being red deer, wild boar and roe deer (Dular and Tecco-Hvala 2007).

The botanical material has provided evidence for a mixture of domesticated plants, including C3 cereals (barley, wheat, oats, and rye), legumes (vetch, faba bean, pea, lentils) and vegetables (cabbage, mustard, turnip and kohlrabi) (Dular and Tecco-Hvala 2007). The charred remains of millet (a C4 plant) grains found in over a dozen late prehistoric sites in south-east Slovenia and northern Croatia, are evidence that this crop was being exploited in this region by the Late Bronze Age, if not earlier (Dular and Tecco-Hvala 2007; Karavanić et al. 2015; Reed and Drnić 2016).

1.3 Stable isotope analysis

The analysis of stable carbon and nitrogen isotopes in human bone and dentine collagen has become commonplace for the investigation of diet in the past (Tykot 2004; Craig et al. 2009; Tafuri et al. 2009;

Killgrove and Tykot 2013; Lightfoot et al. 2014). $\delta^{15}\text{N}$ values have also been used for the investigation of health status, as this ratio is not only reflective of diet, but of an individual's nitrogen balance (Fuller et al. 2004; Fuller et al. 2005; Beaumont et al. 2013; Beaumont et al. 2015). This balance is affected by dietary nitrogen, but also by metabolic processes and states, such as growth, malnutrition, and illness (Mekota et al. 2009; Reitsema 2013; Waters-Rist and Katzenberg 2010). It depends on the amount of nitrogen excreted in relation to the amount of dietary nitrogen ingested. The body falls into a negative nitrogen balance also known as catabolism, or a catabolic state, for example, during periods of nutritional stress or disease (Fuller et al. 2005; Mekota et al. 2009; Beaumont et al. 2013; Beaumont et al. 2015). Catabolism raises $\delta^{15}\text{N}$ values as the body breaks down tissues to replace nitrogen missing from the diet, which results in an increase in the ^{15}N in newly-formed tissues relative to the original, and can be misinterpreted as ingestion of higher trophic level foods. The body enters into a positive nitrogen balance when less nitrogen is excreted than ingested, commonly during times of rapid growth, such as infancy and puberty (Waters-Rist and Katzenberg 2010). This is also known as anabolism, or an anabolic state, and has been reported to lower $\delta^{15}\text{N}$ values (Fuller et al. 2006, Waters-Rist and Katzenberg 2010). This current case study from Early Iron Age Slovenia aims to investigate temporal changes in nitrogen balance in the hard tissues of an infant exhibiting a range of pathological skeletal lesions.

This study illustrates the advantages of bringing together multiple strands of evidence to create more informed interpretations regarding life and death in prehistory. It also demonstrates the importance of context when interpreting stable carbon and nitrogen isotope data.

2. Material and Methods

2.1 Osteological Analysis

Poor preservation can limit the nature of information gleaned from osteological analysis (Bytheway and Ross 2010). The burial conditions within the current study area are predominantly detrimental to bone preservation, leading to severe cortical exfoliation, root etching, as well as a variable level of completeness, frequently 50% or less (Nicholls 2017).

Osteological and palaeopathological analysis was undertaken through macroscopic observation and using a magnifying hand lens. Standard analysis and recording methods were used for biological sex assessment (pelvis: (Walker 2005; Phenice 1969; Klales et al. 2012) skull: (Buikstra and Ubelaker 1994; Walker 2008; İşcan and Steyn 2013)) and age estimation (Buckberry and Chamberlain 2002; Brooks and Suchey 1990; Brothwell 1981). Tooth wear (Brothwell 1981) was used with caution due to a lack of published, calibrated, population-specific standards for the study area. Supporting evidence was taken from late fusing epiphyses (Belcastro et al. 2008; Webb and Suchey 1985). Due to the generally poor preservation of the skeletal material, broad ranges of young, middle and mature adult were considered more appropriate than numerical ages (after Buikstra and Ubelaker, 1994). Standard protocols and guidelines were used for recording the appearance and location of pathological lesions (Buikstra and Ubelaker 1994; Aufderheide and Rodríguez-Martín 1998; Brickley and Ives 2008). Although some radiographs were taken, they were of limited use due to the presence of taphonomic

damage (including the loss of metaphases on all but the right femur of the infant) and soil within the medullary cavities and trabecular spaces. The degree of fragmentation did, however, allow for the observation of the internal structures of some of the long bones.

Age estimation for the infant was carried out using dental development (AlQahtani 2010; Moorrees et al. 1963). Due to the young age of the infant the remains were not assessed for sex.

2.2 Isotope analysis

Stable carbon and nitrogen isotope ratio analysis was carried out on rib collagen from three adults interred within the same site. A rib collagen sample was taken from the infant, in addition to incremental dentine collagen sampling. Care was taken not to sample from an area that exhibited any pathological lesions (Olsen et al. 2014). The study also included faunal material from three cows, two pigs and a deer. Animal bones were excavated from the grave fills and their immediate surroundings. These are, however, unlikely to represent grave goods, and are most probably remains from a settlement, immediately pre-dating the cemetery in this location, and so represent a contemporary faunal baseline of stable carbon and nitrogen isotope ratios for the area.

All collagen extractions were carried out following the modified Longin method (Longin 1971; Brown et al. 1988). Rib fragments (c. 300mg) were demineralised in 0.5M HCl at 4°C, which took between two and four weeks. Once the production of CO₂ had ceased and the reaction was complete, all samples were rinsed three times with deionised water and placed in an HCl solution of pH3 at 70°C for 48 hours to gelatinise. The solutions were filtered using Ezee filters, followed by centrifugal filtering using Millipore ultrafilters. The resulting liquid was then freeze-dried, weighed in duplicate and measured at the University of Bradford Stable Isotope Facility by combustion in a Thermo Flash EA 1112. Internal and external standards were run throughout, as well as separated N₂ and CO₂ reference gases, using a Delta plus XL via a ConFlo III interface. The analytical precision for both the $\delta^{13}\text{C}$ and $\delta^{15}\text{N}$, based on instrumental error, is $\pm 0.2\%$.

For the infant, seven 1mm incremental dentine samples were taken from the crown to the apex of the first right maxillary deciduous incisor, following method 2 from Beaumont et al. (2013). The first right maxillary incisor was selected for stable isotope analysis based on preservation and because this was the most developed of the available teeth. Because of the overlap of dentine layers in each 1mm sample (apart from the first and final sections as the tooth was forming at the time of death) the isotope results will represent a rolling average of dietary input (Beaumont et al. 2013). Temporal resolution is much better than that seen in bone collagen, but the results are discussed in terms of general trends of increasing and decreasing isotope values, rather than attempting to assign exact age to each section.

Isotopic data, together with associated chronological and other supporting information from this study, has been added in the IsoArch database (Salesse et al. 2018; Salesse et al. 2019).

3. Results

3.1 Osteological analysis

The first and second right incisors had complete crowns and $\frac{1}{4}$ roots. The right canine and first molar had yet to erupt from the maxilla, while the crown of the second right molar (loose) was complete, but with no initiation of the root. The stage of development and tooth eruption is consistent with an age of 7.5 months +/- 3 months following AlQahtani (2010). The development of the second molar is consistent with an age of 6-9 months following Moorrees et al. (1963). It was concluded that the infant was 6-9 months old at the time of death based on dental development (AlQahtani 2010; Moorrees et al. 1963). The age and sex determinations of the adult skeletal remains are presented in Table 1.

The preservation and fragmentation of skeletal remains has had considerable consequences for the identification of pathological lesions. Subsequently, it cannot be said that pathological lesions were never present, only that there was no evidence upon examination.

The middle aged adult female buried in grave 8 exhibited cribra orbitalia and diffuse porosity across the cranial vault fragments. Diffuse porosity and compact, striated bone was also identified on surviving fragments of the long bones. Probable systematic non-specific inflammation possibly due to infection or metabolic disease is suggested, however, further diagnosis was not possible due to the fragmented nature of the remains.

No other palaeopathological lesions were observed on the other adults. However, the taphonomic damage to the skeletal remains was very severe, and the cortical surface of these remains was heavily impacted. There is a possibility that any pathological lesions were destroyed in the burial environment.

3.1.1 Palaeopathological analysis of the *Zagorje ob Savi* infant

Some of the pathological lesions described here are depicted in Figure 2. The skeletal remains of the infant exhibited a high prevalence of abnormal porosity. In the cranium, this was noted in the roof of both eye orbits; diffusely across the ectocranial surface of the surviving fragment of frontal bone; and in small patches on both parietal bones around the parietal bosses and the coronal suture. The external areas of the right maxilla (Figure 3A), extending away from the alveolar bone towards the infra-orbital foramen, and the hard palate also exhibited extensive porosity.

Isolated small plaques of porous woven bone were observed on the endocranial surfaces of the parietal bones (Figure 3B) and the squamous portion of the temporal adjacent to the squamous suture. Layers of woven and compact new bone formation were also identified in the roof of the eye orbits (Figure 3C), the external (inferior) surface of the basilar portion (Figure 3D), and on the surface of the left pars lateralis of the occipital, adjacent to the occipital condyle and the hypoglossal canal.

Diffuse plaques of porous sub-periosteal new bone formation were identified on the surviving long bones, specifically; covering the middle third of both femoral and both humeral diaphysis (Figure 3E), the proximal and middle third of the right fibula and the entire surviving fragment of the right tibia (Figure

3F) (the left side being absent). Compact and striated bone was also noted along the linea aspera of the right femur (Figure 3G). The additional surviving fragments from the axial skeleton were too poorly preserved to detect the presence or absence of any pathological lesions.

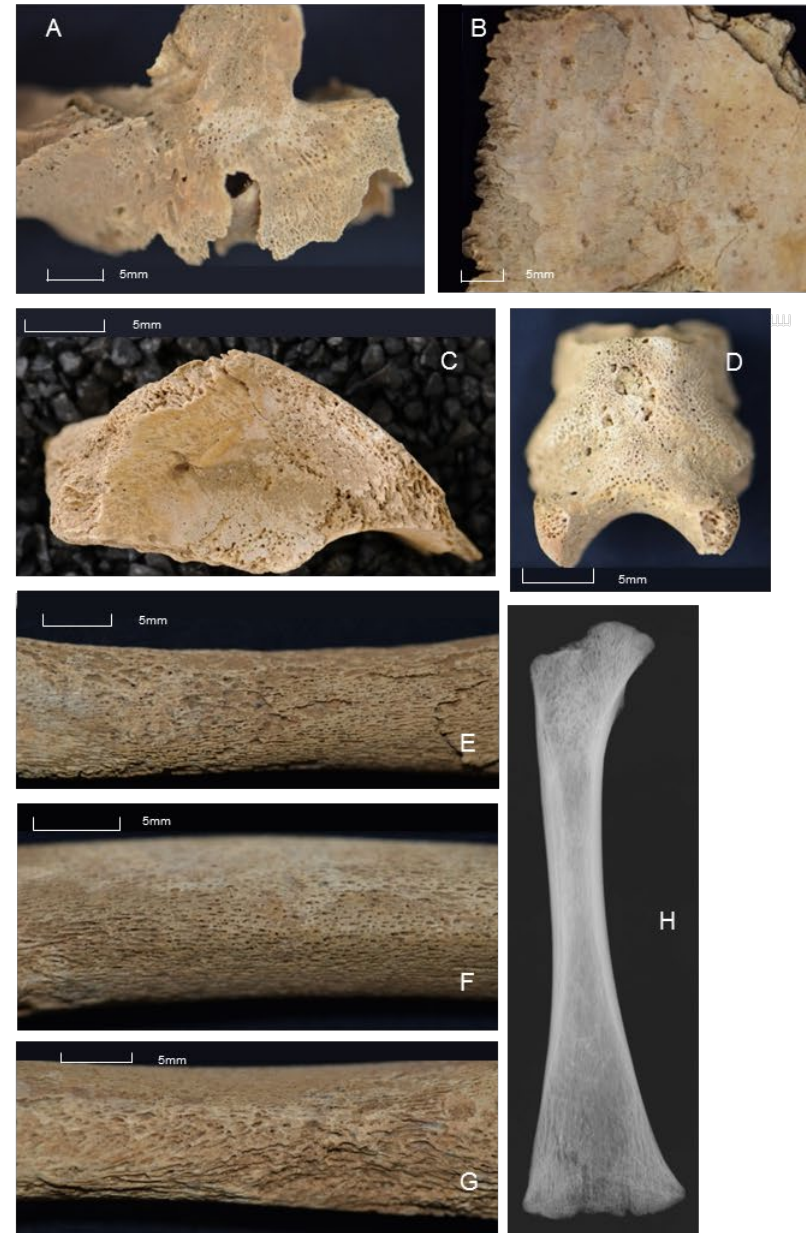
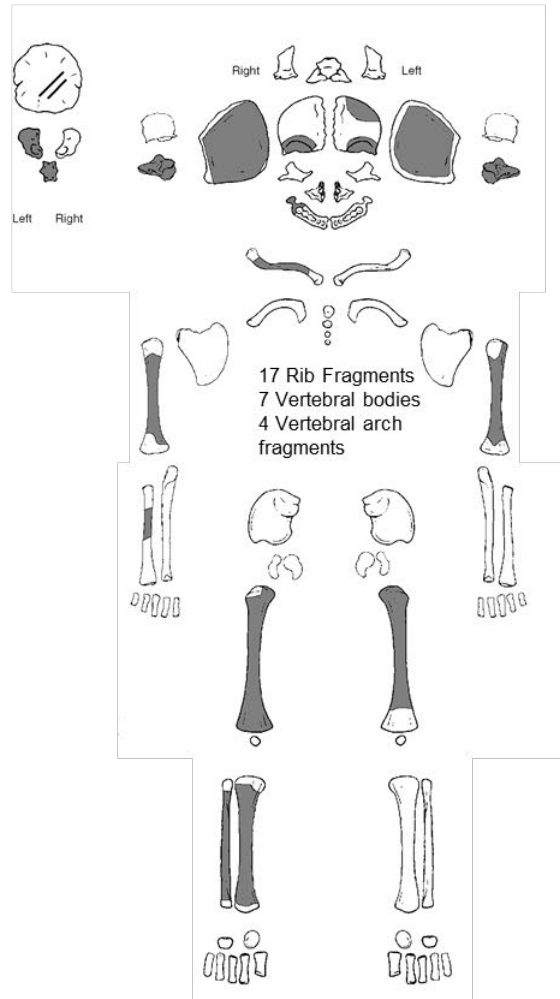


Figure 2. **Left:** Inventory of skeletal remains from the infant; **Right:** **A:** Right maxilla fragment showing porosity around maxillary sinus; **B:** Endocranial surface of parietal bone with plaques of compact bone; **C:** Right orbit with layers of porous woven bone; **D:** Basilar portion with abnormal porosity; **E:** Posterior right humerus showing plaque of porous woven and compact bone on top of original cortical surface; **F:** Anterior right tibia showing plaque of porous woven and compact bone on top of original cortical surface; **G:** Posterior right femur with porous compact bone on and around the linea aspera; **H:** Radiograph of right femur

3.2 Carbon and nitrogen Isotopes

3.2.1 Rib collagen samples of individuals buried at *Zagorje ob Savi*

The stable carbon and nitrogen isotope results of bulk rib collagen from four individuals buried at *Zagorje ob Savi* can be seen in Figure 3 and Table 1. All samples fell within the accepted C:N ratio and >1 % collagen yield, indicating good collagen preservation (Van-Klinken 1999).

Adult rib $\delta^{13}\text{C}$ values range between -15.2 and -14.4‰, and $\delta^{15}\text{N}$ values between 8.6 and 9‰. The collagen extracted from the rib of the infant has considerably higher $\delta^{13}\text{C}$ (+2.9‰) and $\delta^{15}\text{N}$ (+3‰) values when compared to the adult values.

Specimen	Element	Grave No.	Sex	$\delta^{13}\text{C}$ ‰	$\delta^{15}\text{N}$ ‰	C:N	Amt%N	Amt%C
Middle adult*	rib	2	M	-14.8	8.6	3.2	16.7	46.0
Middle adult	rib	8	F	-15.2	8.9	3.2	17.4	47.6
Middle adult	rib	5	F	-14.4	9.0	3.2	17.2	46.8
Infant	rib	7	N/A	-11.9	11.8	3.2	15.3	41.3
Infant dentine (average of whole tooth root)	incisor	7	N/A	-12.1	12.0	3.2	15.9	43.2
Deer	metatarsal	9	N/A	-23.1	3.3	3.3	13.5	38.1
Cow	scapula	5	N/A	-19.0	4.8	3.2	14.9	41.0
Cow	metatarsal	1	N/A	-19.2	6.3	3.2	15.2	41.9
Cow	metatarsal	5	N/A	-18.5	6.7	3.3	14.4	40.5
Pig	mandible	8	N/A	-21.0	6.3	3.2	14.4	40.1
Pig	scapula	8	N/A	-19.3	4.8	3.3	14.0	39.1

Table 1. Carbon and nitrogen ratios from human and faunal remains from *Zagorje ob Savi* (*Middle adult age range 36-50yr, Buikstra and Ubelaker 1994)

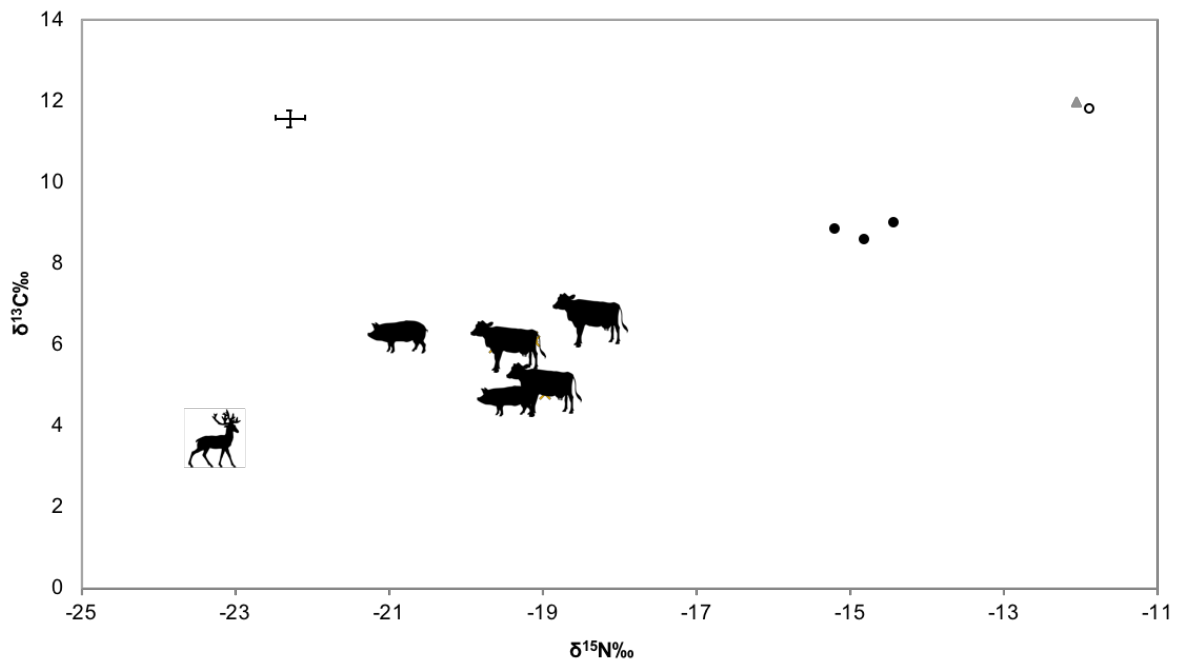


Figure 3. Plot of carbon and nitrogen isotope ratios obtained from the remains of individuals buried at *Zagorje ob Savi*. Samples include rib bone collagen from three adult individuals (black circles) and the rib (white circle) and mean dentine collagen extracted from the Infant (grey triangle). The plot also includes carbon and nitrogen isotope ratios of animal bone collagen sourced from graves in the same cemetery assemblage as the human remains. The error bars represent the analytical precision of carbon and nitrogen isotope analysis, based on instrumental error of $\pm 0.2\%$.

3.2.2. Incremental dentine collagen analysis of a first deciduous incisor from the infant

The results of incremental dentine collagen analysis are shown in Table 2 and Figure 4. Figure 4 displays an increase in both $\delta^{13}\text{C}$ (+1.2‰) and $\delta^{15}\text{N}$ (+2.3‰) values throughout the development of the tooth root. If we accept that this tooth represents tissue from 2 months pre-birth through to 9 months post-birth, (Beaumont and Montgomery 2015) we can see that, in comparison to $\delta^{13}\text{C}$ values, $\delta^{15}\text{N}$ values are observed to increase more rapidly and by a higher magnitude, most notably from section 5 through to death ($\delta^{15}\text{N} = +1.7\%$; $\delta^{13}\text{C} = +0.8\%$).

Dentine increment	$\delta^{13}\text{C} \text{ ‰}$	$\delta^{15}\text{N} \text{ ‰}$	C:N	Amt%N	Amt%C
1 (crown)	-12.6	11.2	3.2	15.8	43.3
2	-12.4	11.4	3.2	14.1	38.4
3	-12.2	11.6	3.2	16.4	44.5
4	-12.1	11.8	3.2	16.8	45.4
5	-12.0	12.1	3.2	16.7	45.1
6	-11.7	12.7	3.2	16.5	45.0
7 (apex)	-11.3	13.5	3.2	14.8	40.6

Table 2. Carbon and nitrogen isotope ratios of dentine increments sampled from the first deciduous incisor, *Zagorje ob Savi* infant

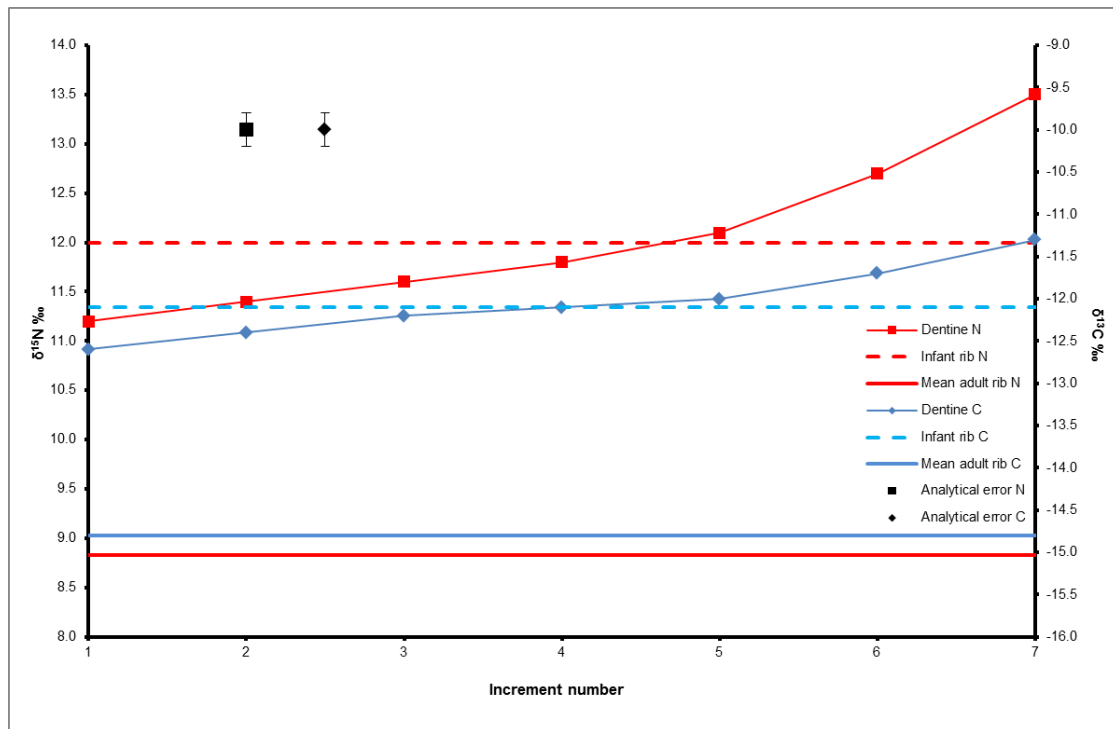


Figure 4. A plot of carbon and nitrogen isotope ratios of incremental dentine sections sampled from the first deciduous incisor of the *Zagorje ob Savi* infant. The red and blue trend lines represent changing metabolic and dietary conditions from pre-birth to around the time of death, reflected through isotopic variation. The red line represents the mean adult rib $\delta^{15}\text{N}$ value of 8.8‰ and the blue line the mean adult rib $\delta^{13}\text{C}$ value of -14.8‰. The red dashed line represents the infant rib $\delta^{15}\text{N}$ value of 11.8‰ and the blue dashed line the infant rib $\delta^{13}\text{C}$ value of -11.9‰. The error bars represent the analytical precision of carbon and nitrogen isotope analysis, based on instrumental error of $\pm 0.2\%$.

4. Discussion

4.1 Pathological lesions

Normal growth and development of the infant skeleton causes areas of porosity because of increased vascularisation, particularly around the growth plates at the metaphyses of long bones (Cunningham et al. 2016). Ortner et al. (2001) suggest that porous lesions that extend 10 mm past the growing metaphyseal end of the diaphysis are less likely to be connected to normal bone growth. Sub-periosteal bone formation has been linked with several pathological conditions, including non-specific inflammation and metabolic disease, such as haemolytic (caused by the premature destruction of red blood cells) or megaloblastic (deficient in vitamin B₁₂ and folic acid) anaemia, rickets (childhood vitamin D deficiency) and scurvy (vitamin C deficiency) (Ortner and Ericksen 1997; Ortner and Mays 1998; Ortner et al. 2001; Brickley and Ives 2006; Mays 2008a; Walker et al. 2009; Snoddy et al. 2018).

4.2. Differential diagnoses

Megaloblastic and haemolytic anaemias can be caused by a range of dietary and genetic factors (Walker et al. 2009). Porosity within the eye orbit and the cranial vault has been linked to anaemia, thought to occur as a response to increased red blood cell production. Expansion of the hematopoietic marrow within the diploë of the skull causes greater vascularisation at the expense of the outer and inner table of the cranial vault (Walker et al. 2009). Whilst porosity was observed at these locations in

the current investigation, the absence of hyperplasia of the diploë and the presence of sub-periosteal new bone formation suggests these lesions were not primarily the result of anaemia (Ortner et al. 2001; Brickley and Ives 2006).

Rickets results from the inability to adequately mineralise bone due to the lack of vitamin D during growth. This produces pores in dry bone as the inadequately mineralised osteoid that once filled these spaces does not survive the burial environment (Ortner and Mays 1998; Mays et al. 2006). It is commonly associated with the deformation of long bones and sternal rib ends, as well as a roughened bone surface beneath epiphyseal joint plates. As some of these deformities are related to weight bearing whilst crawling or walking, it is unlikely they would be visible in the lower limbs of this infant. Bony changes have been recognised in infants as young as 3 months, affecting the upper limb, ribs, orbital roof, cranial vault, and growth plates (Ortner and Mays 1998). A pattern of struts and slits across major long bones were also observed by Ortner and Mays (1998), showing that rickets is diagnosable in infants who have not yet begun walking. In the *Zagorje ob Savi* case, macroscopic and radiographic (right femur; Figure 3H) observations did not identify deformation of the long bones, struts or slits near the metaphyses, and the one surviving metaphyseal surface (right, proximal femur) appeared normal. This makes a diagnosis of rickets unlikely.

Non-specific inflammation involving the periosteum can also result in abnormal bone porosity (Lewis 2004; Weston 2008). Plaques of new bone on top of the original cortical surface of long bones have also been associated with an inflammatory response to non-specific infection (Roberts and Manchester 2010). Whilst this type of lesion was observed in the *Zagorje ob Savi* infant, Ortner (2003) has cautioned that under the age of four, woven periosteal new bone at this location this cannot be differentiated from normal bone growth. Thus, whilst non-specific inflammation due to a systemic infection cannot be ruled out there is insufficient skeletal evidence to make this diagnosis.

The *Zagorje ob Savi* infant exhibits several features that have been associated with scurvy. Using criteria suggested from Snoddy et al's (2018) synthesis of clinical and palaeopathological studies, we have highlighted skeletal lesions that have been described as 'suggestive' or 'diagnostic' (see Table 3).

Lesion Location	Lesion type	Proposed diagnostic strength
Frontal orbital roof	Bilateral sub-periosteal new bone	Diagnostic
Right maxilla: Anterior surface/ infra-orbital foramen	Abnormal cortical porosity	Diagnostic
Right maxilla: palatal surface	Abnormal cortical porosity	Diagnostic
Ectocranial parietal	Abnormal cortical porosity	Diagnostic
Endocranial parietal and squamous temporal	Islands of abnormal cortical porosity and sub-periosteal new bone	Suggestive
Occipital inferior surface: pars basilaris	Abnormal cortical porosity and sub-periosteal new bone	Suggestive
Femur: linea aspera	Sub-periosteal new bone	Suggestive
Appendicular skeleton: diaphysis	Sub-periosteal new bone (diffuse)	Diagnostic*

Table 3: Macroscopic lesions that have been attributed to scurvy (Snoddy et al. 2018) *not exclusive to scurvy

There are only two additional features described by Snoddy et al. as 'diagnostic' and these are found on the sphenoid and scapulae bones. Unfortunately, in the current case, these elements were absent and, therefore, could not be assessed. However, we have identified five criteria thought to be diagnostic of scurvy and others that are suggestive (Table 3). Additionally, Ortner et al. (2001) have argued that scurvy can affect the skeleton without involving the greater wing of the sphenoid and Brickley and Ives (2006) have cautioned against the over-dependence on one skeletal element for the diagnosis of pathology.

Scurvy occurs when there is insufficient vitamin C intake. This micronutrient is responsible for the correct formation of collagen (Munday et al. 2005; Tsuchiya and Bates 2003). Collagen is a structural protein that is ubiquitous within the human body contributing to the formation of skin, muscle, tendon, the lining of vital organs, as well as bones and teeth. A lack of vitamin C can thus result in weakened connective tissues and vessels that are susceptible to haemorrhage (Hirschmann and Raugi 1999). Chronic bleeding of tissues adjacent to the bone surface can lead to an inflammatory response, i.e. porosity and sub-periosteal new bone formation (Mays 2008b). The pathological lesions consistent with scurvy have been argued to be more common in the skeletal remains of young children because of the high demands of rapid growth (Ortner and Ericksen 1997; Ortner et al. 1999). As the child develops, poor collagen formation leads to arrested osteoblastic activity and the collagenous bone matrix does not ossify.

The new bone growth identified across the skull and long bones was formed on top of the existing cortical surface, consistent with haemorrhage resulting from minor trauma, for instance lesions in the eye orbit may be caused by the movement of the ocular muscles (Lewis 2004; Mays 2008a; Moore and Koon 2017; Walker et al. 2009). The plaques of compact bone identified on the endocranial surface of the skull, in conjunction with the layers of woven and compact bone observed within the orbits and on the long bone diaphyses, suggest that there were phases of recovery and healing, as new bone could only have been laid down during a recovery phase following the reintroduction of vitamin C (Brickley and Ives 2006). The lesions are, therefore, consistent with chronic scurvy with some evidence of reintroduction of vitamin C prior to death (Brickley and Ives 2006; Mays 2008a; Walker et al. 2009).

It is important to note that a malnourished individual could suffer from more than one disease or condition. The occurrence of one can weaken the immune system, causing the individual to become more susceptible to other illnesses. The individual presented here may have been additionally affected by any of the disorders mentioned above, as well as other deficiencies and infections that do cause skeletal changes. Overall, it was concluded that this infant had suffered from severe and chronic malnutrition, resulting in vitamin C deficiency and probable scurvy.

Clinical symptoms associated with scurvy become identifiable after 1-3 months of insufficient vitamin C intake, depending on existing body stores (Hodges et al. 1969; Larralde et al. 2007) and haemorrhages only after around 6 months of total absence of vitamin C (Hodges et al. 1971). Given the presence of bony lesions on the infant skeleton it is likely they suffered from a chronic deficiency of vitamin C.

It is known from modern-day cases of infantile scurvy that abnormal collagen formation can lead to bleeding in the skin, mucous membranes, muscles, gastrointestinal tract and around the joints (Jackson and Park 1935; Larralde et al. 2007; Weinstein et al. 2001). Individuals suffering from scurvy may also have difficulties with coagulation of the blood, which can exacerbate the problem and lead to complications with healing wounds (Larralde et al. 2007). Clinical symptoms include fatigue, irritability, and delayed or stunted development. Haemorrhagic skin lesions are common, and haemorrhaging from the eyelids and gums has also been described (Larralde et al. 2007; Weinstein et al. 2001).

Swelling of the lower extremities has been observed, potentially with multiple causalities, including leaking capillaries and soft tissue haemorrhage (Larralde et al. 2007). Intense joint pain and muscle weakness, especially in the lower limbs, constricts movement and leads to children laying in an abduct or 'frog-like' position (Larralde et al. 2007). Therefore, the *Zagorje ob Savi* case of probable infantile scurvy would have resulted in particularly visible symptoms.

4.3 Carbon and nitrogen isotopes

4.3.1 Animal bone collagen

There is a small shift in the carbon and nitrogen isotope ratios between wild (i.e. deer) and domesticated animals. This is probably due to the higher levels of controlled feeding in domesticated animal populations, including potential penning, which can raise $\delta^{15}\text{N}$ values if animals are consuming vegetation grown in ^{15}N enriched soil by their faeces, and foddering, where fodder may have similarly been grown on land enriched in ^{15}N from manure (Bogaard et al. 2007; Fraser et al. 2011). Additionally, if this fodder included C_4 plants (grain or crop waste), $\delta^{13}\text{C}$ values would also be increased relative to non-foddered animals (Tieszen 1991; Tafuri et al. 2009). If the deer were living under heavily forested conditions, the $\delta^{13}\text{C}$ values produced from their bone collagen could be reflecting the 'canopy effect', where plants become depleted in ^{13}C because of either reduced light intensity or recycled CO_2 (Bonafini et al. 2013; Noe-Nygaard et al. 2005; Van der Merwe and Medina 1991). This depletion is then transmitted up the food chain. If this were the case, the consumption of vegetation under forest conditions could mask the consumption of native C_4 species.

When the human carbon and nitrogen isotope data is compared to the animal baseline, the predicted trophic level shift of c.2-5‰ between humans and most herbivores is present (Ambrose 1991; Hedges and Reynard 2007). This supports the interpretation that humans were ingesting herbivorous animal protein, either dairy or meat.

4.3.2. Human bone and dentine collagen

The $\delta^{13}\text{C}$ and $\delta^{15}\text{N}$ values produced as part of this study are indicative of a terrestrial-based diet, with a focus on a mix of C_3 and C_4 plants, probably millet, with the addition of herbivorous animal protein

(Hedges and Reynard 2007; Richards 2003; Tieszen 1991; Tykot 2004). This is consistent with contemporary faunal and botanical evidence (Dular and Tecco-Hvala 2007).

Isotopically, there is a clear difference between the bone (and dentine) collagen of the infant and the three contemporaneous adults from *Zagorje ob Savi* (Figures 3 and 4). On first examination, and given the age of the infant (6-9 months), this elevated $\delta^{15}\text{N}$ value is likely linked to breastfeeding. High $\delta^{15}\text{N}$ values have been linked to breastfeeding practices in previous isotopic studies (Beaumont et al. 2013; Fuller et al. 2006; Jay et al. 2008; King et al. 2018; Millard 2000). Modern data (infant hair and nail) has demonstrated that breastfeeding results in a rapid trophic level shift in $\delta^{15}\text{N}$ of 1.5‰ (de Luca et al. 2012) and up to 2-3‰, (Fuller et al. 2006) above birth values. This rise occurs as the infant ingests the proteins of their mother via breastmilk, which results in additional isotopic fractionation in comparison to the maternal $\delta^{15}\text{N}$ values (Fogel et al. 1989). $\delta^{15}\text{N}$ drops gradually to a value similar to the mother throughout the process of weaning (introduction of solid foods commonly combined with continued nursing) and the cessation of breastfeeding, provided the mother and child are sharing a similar diet (Fuller et al. 2006; Jay et al. 2008; Millard 2000) (see Supplementary 2). A smaller trophic shift of 0.4 and 1‰ in $\delta^{13}\text{C}$ values has similarly been observed (de Luca et al. 2012; Fuller et al. 2006; Tsutaya and Yoneda 2015).

The ~2‰ difference between the first infant dentine increment and the mean adult rib $\delta^{15}\text{N}$ value fits this breastfeeding pattern. $\delta^{15}\text{N}$ values continue to rise throughout the development of the dentine, a trend that similarly supports the interpretation of a trophic shift consistent with breastfeeding. The difference of 3‰ between the adult and infant rib collagen $\delta^{15}\text{N}$ values is also consistent with a trophic shift related to breastfeeding. When viewed at face value, the infant isotope profiles presented here can reasonably be associated with the onset and continuation of exclusive breastfeeding. However, the first increment (which will include pre-natal dentine) is already comparatively high, and there is a gradual rise in the $\delta^{15}\text{N}$ values rather than the rapid upward curve expected (see Supplementary 2). $\delta^{15}\text{N}$ values for the infant then rise sharply through the final three increments prior to death. $\delta^{13}\text{C}$ values follow a similar trend. The final increment of infant dentine (representing the time of death) has a $\delta^{15}\text{N}$ value 4.7‰ above that of the mean adult rib value, while the $\delta^{13}\text{C}$ value is 3.5‰ above the adults. Both of these differences in isotope ratios are greater than that anticipated from breastfeeding alone. Indeed, $\delta^{13}\text{C}$ and $\delta^{15}\text{N}$ from rib collagen (-11.9‰ $\delta^{13}\text{C}$; 11.8‰ $\delta^{15}\text{N}$) for this infant was notably higher than for other rib collagen samples from across Iron Age Slovenia, with mean $\delta^{13}\text{C}$ and $\delta^{15}\text{N}$ values of -15.3‰ and 9.1‰, respectively (Nicholls and Koon 2016; Nicholls 2017). With the additional context of chronic dietary deficiencies, the isotope data indicates a more nuanced interpretation.

5. Interpretations

The following presents some potential scenarios, which could explain the variation in carbon and nitrogen isotope ratios observed between the infant and associated adults.

5.1 Dietary change

The high $\delta^{13}\text{C}$ and $\delta^{15}\text{N}$, particularly in the initial incremental dentine samples of the infant, suggest a possible change in maternal diet over time. The high $\delta^{13}\text{C}$ values ranging between -12.6‰ and -11.3‰ indicate either a substantial marine or C_4 dietary input and are considerably higher than that of the isotope ratios obtained from the three adults ($+3 - 4\text{‰}$). The ingestion of marine food is unlikely given the location of the cemetery, but also there is no isotopic or faunal evidence (to date) for the consumption of marine food during prehistory in Slovenia (Murray and Schoeninger 1988; Nicholls and Koon 2016). There is, however, substantial evidence for the consumption of C_4 plants in the wider area during the Late Bronze and the Iron Age, namely millet (Dular and Tecco-Hvala 2007; Lightfoot et al. 2014; Murray and Schoeninger 1988; Nicholls and Koon 2016; Reed and Drnić 2016). The adult individuals buried at *Zagorje ob Savi* also provide evidence of C_4 plant consumption. It is posited, then, that a substantial amount of the dietary carbon for the infant was obtained from millet, and that the amount of millet ingested increased with time, as indicated by the increase in $\delta^{13}\text{C}$ values throughout the development of the tooth.

This is not to say that the infant was ingesting millet as a grain—given the age of the individual it is unlikely that they were eating solids—but that the C_4 isotope signature was being transmitted indirectly into their diet through another route. This signal may have initially been introduced to the foetus in-utero via the mother. If the infant was nursing, the gradually increasing $\delta^{13}\text{C}$ values could indicate that the mother was also ingesting increasing quantities of millet whilst breastfeeding. In addition, a small portion of the increase (i.e. 0.4-1.0 per mil) could be caused by the small carbon isotope breastfeeding trophic shift.

While this explains the carbon isotope values, it does not account the rapid increase in nitrogen isotope values observed in the latter three increments. The ingestion of millet would not result in elevated $\delta^{15}\text{N}$. Additionally, the increase in $\delta^{15}\text{N}$ is beyond the trophic level shift associated with breastfeeding. This suggests that isotopic changes are not solely the result of a change in diet.

5.2 Nutritionally stressed mother equals nutritionally stressed child

Studies have shown that the nitrogen isotope ratios of children are complex, linking high $\delta^{15}\text{N}$ values to changes in metabolism, maternal health, or falling into a negative nitrogen balance resulting in tissue catabolism (Beaumont et al. 2015; Reynard and Tuross 2015). When the body does not receive required dietary nitrogen (e.g. needed for protein synthesis), it instead obtains it from its own tissues. This breakdown of body tissues, known as catabolism, causes isotopic fractionation as molecules containing the lighter isotope, ^{14}N , break down more readily. This results in an enrichment of the heavier isotope, ^{15}N , in the tissues that are then sampled for isotopic analyses (Mekota et al. 2009). Increased $\delta^{15}\text{N}$ values have been linked to malnutrition on several occasions (Hobson et al. 1993 (animal); Fuller et al. 2005; Mekota et al. 2009 (clinical); Beaumont et al. 2015 (archaeological)). If the mother of the

infant was severely malnourished, this would have had a negative impact on their child. Studies into archaeological dentine and modern hair and breast milk samples have suggested that high $\delta^{15}\text{N}$ values in infants are not exclusively the result of the ingestion of breastmilk (Beaumont et al. 2013; Beaumont et al. 2015; Beaumont and Montgomery 2016; de Luca et al. 2012; Romek et al. 2013). In the current study, $\delta^{15}\text{N}$ values continue to rise post-birth, beyond the trophic shift associated with breastfeeding. This may reflect the mother's continued metabolic status, in addition to her diet. It might equally reflect undernutrition in the infant to the extent that they are beginning to recycle their own tissues (Beaumont and Montgomery 2016).

When examining the earliest incremental dentine sections, probably including dentine formed in-utero, the high nitrogen isotope ratios could actually be reflecting a mother in the third trimester of pregnancy. The unborn foetus would have obtained its nutrients directly from the mother across the placenta, thereby transferring the maternal isotope ratios into the forming tissues of the unborn baby (Beaumont et al. 2015). $\delta^{15}\text{N}$ values influenced by dentine formed prior to birth are notably higher than that of the three adult rib values (c.+2.4‰ between the mean adult rib $\delta^{15}\text{N}$ value and the first dentine increment of the infant). As discussed above, this $\delta^{15}\text{N}$ value may be indicative of the nitrogen balance of a physiologically stressed mother.

At this point, to understand more fully the comparatively high $\delta^{15}\text{N}$ values (and comparatively smaller corresponding increase in $\delta^{13}\text{C}$ values) from the bones and teeth of the infant, it is vital to consider the probable diagnosis of chronic scurvy. A lack of dietary vitamin C alone does not cause starvation or increased $\delta^{15}\text{N}$ values associated with catabolism. In fact, clinical paediatric studies have shown normal weight gain in children with vitamin C deficiency, but an otherwise normal diet (Weinstein et al. 2001). Nevertheless, there are several reasons why scurvy may have been a factor in causing malnutrition. Symptoms of scurvy include painful and bleeding gums and irritability in infants; this may well have caused difficulties with feeding and suckling (Larralde et al. 2007). Also, vitamin C deficiencies are often linked to other nutrition deficiencies and co-morbidities (Schattmann et al. 2016), such as infections, that would exacerbate feeding problems and could themselves lead to malnutrition (Nguyen et al. 2013). A deficiency in vitamin C can also inhibit the absorption of iron from the small intestine, leading to iron deficiency anaemia (Brickley and Ives 2006; Weinstein et al. 2001) and leaving the infant more susceptible to infection and disease due to an under-developed immune system (Siegel, 1993; Thomas and Holt, 1978).

Even though there is evidence to suggest the mother was malnourished during pregnancy and breastfeeding, this should not normally have caused the skeletal manifestations associated with scurvy observed in these infant remains. It is known that breast milk usually contains enough nutrition for an infant to thrive without additions to their diet, including water, for the first 6 months (Larralde et al. 2007; WHO 2005). The minimum required intake of vitamin C for infants is unestablished; however, the recommended daily allowance for 0 to 12 months varies from 35-50mg (Byerly and Kirskey, 1985; NIH 2018; NRC 1989), which is well within the range of vitamin C available in breastmilk (Byerly and Kirskey, 1985) even in marginally nourished women with low serum vitamin C levels (Ahmed et al. 2004). During

periods of short term stress, pregnant or lactating women will generally route necessary nutrients to the foetus or milk production at their own expense (Ahmed et al. 2004; Bates and Prentice 1994; Byerly and Kirskey 1985). For a breastfed infant of this age (6-9 months) to exhibit such severe nutritional deficiencies, the mother must also have suffered from severe malnutrition (Bates and Prentice 1994; Jackson and Park 1935). This has been demonstrated in very rare clinical cases of congenital scurvy, where it is likely that the mother herself suffered from the disease whilst pregnant or lactating (Hirsch et al. 1976; Jackson and Park 1935).

This interpretation of the mother's health status should be treated with caution. The infant was buried in an individual grave and even had they been buried with an adult, it would be impossible to relate individuals without the use of aDNA, which could not be done in this instance. Furthermore, if it had been possible to identify the mother the slower rate of bone turnover in adults means that it is unlikely specific nutritional stress during pregnancy would be detectable in the rib collagen of the mother.

5.3 Supplementation with animal milk?

One possibility that could account for both the high $\delta^{13}\text{C}$ and $\delta^{15}\text{N}$ values (relative to adult rib collagen) is that they were the result of the ingestion of animal milk, as an emergency replacement or supplement for breastmilk, where the animal had been foddered on millet. As stated above, a successfully breastfed infant should not suffer from scurvy, as breast milk provides a good source of vitamin C. If a scenario arose where dietary supplementation was required, the ingestion of unmodified animal milk, for example bovine milk, by young infants (c. <12 months) is particularly unhealthy (Fleischer Michaelsen et al. 2000; Binns et al. 2007). Animal milk as a substitute for breastfeeding is a potential cause for this infant's illness, as cow's milk and goat's milk are deficient in vital nutrients, including vitamin C. The consumption of cow's milk by infants under the age of 12 months can cause blood loss from the gastrointestinal tract, also leading to iron deficiency, anaemia and diarrhoea (Binns et al. 2007; Wijndaele et al. 2009; Griebler et al. 2016). Although the ingestion of animal milk itself would not lead to raised $\delta^{15}\text{N}$ values, the consequences to the health of an infant could result in a compromised immune system and illness, which, in turn could have resulted in tissue catabolism and ^{15}N enrichment.

Overall, it is not possible to establish which of these scenarios was most likely. All, some or none of these scenarios could account for the isotopic and osteological evidence presented in this case study. It is clear that multiple factors can affect the interpretation of stable isotope data and palaeopathological lesions. It is, therefore, vital that any interpretations are augmented with all available contextual information.

6. Conclusion

The infant presented here suffered from severe and chronic malnutrition, probably scurvy. This has been supported by both the stable isotope data and osteological observations. The rib and dentine collagen from the infant suggest that the mother was malnourished during pregnancy passing on high $\delta^{13}\text{C}$ and $\delta^{15}\text{N}$ values to the tissues of the child. The isotope ratios of the adults presented in the current

investigation are consistent with those found at a regional scale. The infant buried at *Zagorje ob Savi* had the highest rib collagen $\delta^{13}\text{C}$ and $\delta^{15}\text{N}$ values of the whole data set spanning central and eastern Slovenia, and northern Croatia, dating from the Bronze Age to the Late Iron Age. The combination of these findings and the palaeopathological status of this infant singled out this individual out as an interesting case study.

In the past, $\delta^{13}\text{C}$ and $\delta^{15}\text{N}$ values obtained from the tissues of infants have been linked to breastfeeding practices alone. Here we can see a pattern that could suggest breastfeeding, but is overlaid by higher $\delta^{13}\text{C}$ and $\delta^{15}\text{N}$ values than would be predicted by the rib samples from the adults. This case study offers several alternative scenarios and supports the argument that isotopic data are complex and should not be interpreted in isolation. Through the application of novel, high resolution sampling methods, in combination with osteological techniques, it has been possible to establish a more nuanced understanding of the complex life history of an infant buried in the Early Iron Age cemetery at *Zagorje ob Savi*, Slovenia.

Acknowledgements

The authors would like to thank the following individuals for their contributions and support: all those involved in the ENTRANS Project (Encounters and Transformations in Iron Age Europe), especially our project manager, Lindsey Büster and the ENTRANS project partners and Hrvoje Potrebica. Thanks to the National Museum of Slovenia, Miha Murko and Matej Draksler for access to the skeletal material and contextual information. For assistance with isotopic measurements we would like to recognise the support of Marise Gorton, Jacqueline Towers and Andy Gledhill at the Bradford University Light Stable Isotope Facility. Thanks to Rachel Kershaw for providing the map. Lastly, the authors would like to thank Dr Keith Manchester, Jo Moore and Laura Castells Navarro for their feedback during the osteological analysis. We would also like to thank the three anonymous reviewers for their comments, which we feel have improved the paper.

Funding information

This project has received funding from the European Union's Seventh Framework Programme for research, technological development and demonstration under grant agreement no 291827. The project is financially supported by the HERA Joint Research Programme (www.heranet.info) which is co-funded by AHRC, AKA, BMBF via PT-DLR, DASTI, ETAG, FCT, FNR, FNRS, FWF, FWO, HAZU, IRC, LMT, MHEST, NWO, NCN, RANNÍS, RCN, VR and The European Community FP7 2007-2013, under the Socio-economic Sciences and Humanities programme.

Bibliography

Ahmed, L., Islam, S. K., Khan, N. I., & Nahid, S. N. (2004). Vitamin C content in human milk (colostrum, transitional and mature) and serum of a sample of Bangladeshi mothers. *Malaysian journal of nutrition*, 10(1), 1-4.

- AlQahtani, S. j. (2010). Brief Communication: The London Atlas of Human Tooth Development and Eruption. *American Journal of Physical Anthropology* 142, 481–490.
- Ambrose, S. H. (1991). Effects of diet, climate and physiology on nitrogen isotope abundances in terrestrial foodwebs. *Journal of Archaeological Science* 18 (3), 293-317.
- Aufderheide, A.C., and Rodríguez-Martín C. (1998). *The Cambridge Encyclopaedia of Human Palaeopathology*. Cambridge University Press: Cambridge.
- Bates, C. J. and Prentice, A. (1994). Breast milk as a source of vitamins, essential minerals and trace elements. *Pharmacology & Therapeutics* 62 (1), 193-220.
- Beaumont, J., Gledhill, A., Lee-Thorp, J. and Montgomery, J. (2013). Childhood Diet: A Closer Examination of the Evidence from Dental Tissue Using Stable Isotope Analysis of Incremental Human Dentine. *Archaeometry* 55 (2), 277-295.
- Beaumont, J., Montgomery, J., Buckberry, J. and Jay, M. (2015). Infant mortality and isotopic complexity: New approaches to stress, maternal health, and weaning. *American Journal of Physical Anthropology*, 157(3), 441–457.
- Beaumont, J. and Montgomery, J. (2015) Oral histories: a simple method of assigning chronological age to isotopic values from human dentine collagen. *Annals of Human Biology*, 42, 407-414
- Beaumont, J. and Montgomery, J. (2016). The Great Irish Famine: identifying starvation in the tissues of victims using stable isotope analysis of bone and incremental dentine collagen. *PLoS One*, 11(8), e0160065.
- Belcastro, M. G., Rastelli, E. and Mariotti, V. (2008). Variation of the degree of sacral vertebral body fusion in adulthood in two European modern skeletal collections. *American Journal of Physical Anthropology* 135 (2), 149-160
- Binns, C. W., Graham, K. I., Scott, J. A. and Oddy, W. H. (2007). Infants who drink cows milk: a cohort study. *Journal of paediatrics and child health* 43 (9), 607-610.
- Bogaard, A., Heaton, T. H. E., Poulton, P. and Merbach, I. (2007). The impact of manuring on nitrogen isotope ratios in cereals: archaeological implications for reconstruction of diet and crop management practices. *Journal of Archaeological Science* 34 (3), 335-343.
- Bonafini, M., Pellegrini, M., Ditchfield, P. and Pollard, A. M. (2013). Investigation of the 'canopy effect' in the isotope ecology of temperate woodlands. *Journal of Archaeological Science* 40 (11), 3926-3935.
- Brickley, M. and Ives, R. (2006). Skeletal manifestations of infantile scurvy. *American Journal of Physical Anthropology* 129 (2), 163-172.
- Brickley, M. and Ives, R. (2008). *The Bioarcheology of Metabolic Bone Disease*. Academic Press. Oxford.
- Brooks, S. and Suchey, J. M. (1990). Skeletal age determination based on the os pubis: A comparison of the Acsádi-Nemeskéri and Suchey-Brooks methods. *Human Evolution* 5 (3), 227-238.
- Brown, T. A., Nelson, D. E., Vogel, J. S. and Southon, J. R. (1988). Improved collagen extraction by modified Longin method. *Radiocarbon* 30, 171-177.

- Brothwell, D. (1981) *Digging up Bones*. 3rd edition. Oxford: Oxford University Press. 59-61
- Byerly L.O. & Kirskey, A. (1985). Effects of different level of vitamin C intake on the vitamin C concentration in human milk and the vitamin C intake of breastfed infants. *American Journal Clinical Nutrition* 41, 665-71.
- Bytheway, J. A. and Ross, A. H. (2010). A Geometric Morphometric Approach to Sex Determination of the Human Adult Os Coxa. *Journal of Forensic Sciences* 55 (4), 859-864.
- Buckberry, J. L. and Chamberlain, A. T. (2002). Age estimation from the auricular surface of the ilium: A revised method. *American Journal of Physical Anthropology* 119 (3), 231-239.
- Buikstra, J. E. and Ubelaker, D. H. (1994). *Standards for data collection from human skeletal remains*. Arkansas Archeological Survey Research Series. Vol. 44. Fayetteville: Wiley Subscription Services, Inc., A Wiley Company.
- Craig, O. E., Biazzo, M., O'Connell, T. C., Garnsey, P., Martinez-Labarga, C., Lelli, R., Salvadei, L., Tartaglia, G., Nava, A., Renò, L., Fiammenghi, A., Rickards, O. and Bondioli, L. (2009). Stable isotopic evidence for diet at the Imperial Roman coastal site of Velia (1st and 2nd Centuries AD) in Southern Italy. *American Journal of Physical Anthropology* 139 (4), 572-583.
- Cunningham, C., Scheuer, L., & Black, S. (2016). *Developmental juvenile osteology*. New York: Academic Press.
- de Luca, A., Boisseau, N., Tea, I., Louvet, I., Robins, R. J., Forhan, A., Charles, M.-A. and Hankard, R. (2012). $\delta^{15}\text{N}$ and $\delta^{13}\text{C}$ in hair from newborn infants and their mothers: a cohort study. *Pediatric research* 71 (5), 598-604.
- Draksler, M. (2007). Območje Zagorja ob Savi v prazgodovini / Das Gebiet von zagorje ob Savi in der Vorgeschichte. – *Arheološki vestnik* 58, 121-155.
- Draksler, M. (2011). *Construction of municipal works the road infrastructure in the SBK national in Zagorje ob Savi*. The municipality of Zagorje ob Savi.
- Draksler, M. and Murko, M. (2020), Nove najdbe iz starejše železne dobe v Zagorju ob Savi / New finds from the Early Iron Age in Zagorje ob Savi. – *Arheološki vestnik* 71 (in press).
- Dular, J. and Tecco-Hvala, S. (2007). *South-Eastern Slovenia in the Early Iron Age*. Opera Instituti Archaeologici Sloveniae Ljubljana: Institute of Archaeology at ZRC SAZU in association with ZRC Publishing, 127-129, 206-213.
- Fleischer Michaelsen, K., Weaver, L., Branca, F. and Robertson, A. (2000). Feeding and nutrition of infants and young children(guidelines for the WHO European Region, with emphasis on the former Soviet countries). *OMS. Publications régionales. Série européenne*.
- Fogel, M.L., Tuross, N. and Owsley, D.W. (1989). Nitrogen isotope tracers of human lactation in modern and archaeological populations. *Carnegie Institution of Washington Yearbook*, (88),111-117.
- Fraser, R. A., Bogaard, A., Heaton, T., Charles, M., Jones, G., Christensen, B. T., Halstead, P., Merbach, I., Poulton, P. R., Sparkes, D. and Styring, A. K. (2011). Manuring and stable nitrogen isotope ratios in cereals and pulses: towards a new archaeobotanical approach to the inference of land use and dietary practices. *Journal of Archaeological Science* 38 (10), 2790-2804.
- Fuller, B. T., Fuller, J. L., Harris, D. A. and Hedges, R. E. (2006). Detection of breastfeeding and weaning in modern human infants with carbon and nitrogen stable isotope ratios. *American Journal of Physical Anthropology* 129 (2), 279-93.

- Fuller, B. T., Fuller, J. L., Sage, N. E., Harris, D. A., O'Connell, T. C. and Hedges, R. E. (2005). Nitrogen balance and $\delta^{15}\text{N}$: why you're not what you eat during nutritional stress. *Rapid Commun Mass Spectrom* 19 (18), 2497-506.
- Fuller, B. T., Fuller, J. L., Sage, N. E., Harris, D. A., O'Connell, T. C. and Hedges, R. E. M. (2004). Nitrogen balance and $\delta^{15}\text{N}$: why you're not what you eat during pregnancy. *Rapid Communications in Mass Spectrometry* 18 (23), 2889-2896.
- Gabrovec, S. (1966). Zagorje v prazgodovini / Zagorje in der Vorgeschichte. – *Arheološki vestnik* 17, 19-36, T. 5-8.
- Griebler, U., Bruckmüller, M. U., Kien, C., Dieminger, B., Meidlinger, B., Seper, K., Hitthaller, A., Emprechtlinger, R., Wolf, A. and Gartlehner, G. (2016). Health effects of cow's milk consumption in infants up to 3 years of age: a systematic review and meta-analysis. *Public health nutrition* 19 (02), 293-307.
- Hedges, R. E. M. and Reynard, L. (2007). Nitrogen isotopes and the trophic level of humans in archaeology. *Journal of Archaeological Science* 34 (8), 1240-1251.
- Hirsch, M., Mogle, P., & Barkli, Y. (1976). Neonatal scurvy. *Pediatric radiology*, 4(4), 251-253.
- Hirschmann, J.V., and Raugi, G.J. (1999). Adult scurvy. *Journal of the American Academy of Dermatology*, 41 (6), 895-910.
- Hobson, K., Alisauskas, R. and Clark, R. (1993). Stable-Nitrogen Isotope Enrichment in Avian Tissues Due to Fasting and Nutritional Stress: Implications for Isotopic Analyses of Diet. *The Condor* 95, 388-394.
- Hodges, R.E., Hood, J., Canham J.E., Sauberlich H.E., Baker E.M. (1971). Clinical manifestations of ascorbic acid deficiency in man. *American Journal of Clinical Nutrition* 24, 432–443.
- Hodges, R. E., Baker, E. M., Hood, J., Sauberlich, H. E., & March, S. C. (1969). Experimental scurvy in man. *The American journal of clinical nutrition*, 22(5), 535-548.
- İşcan, M. Y. and Steyn, M. (2013). *The human skeleton in forensic medicine*. Charles C Thomas Publisher. 160-169.
- Jackson, D. and Park, E. A. (1935). Congenital scurvy: A case report. *The Journal of Pediatrics* 7 (6), 741-753.
- Jay, M., Fuller, B. T., Richards, M. P., Knusel, C. J. and King, S. S. (2008). Iron Age breastfeeding practices in Britain: isotopic evidence from Wetwang Slack, East Yorkshire. *American Journal of Physical Anthropology* 136 (3), 327-37.
- Karavanič, S., Kudelić, A., Mareković, S. (2015). Bronačnodobni tragovi prehrane na Kalniku – sačuvani u vatri. / Tarces of Bronze Age nutrition on the Kalnik – preserved ba fire. *Cris: Časopis Povjesnog društva Križevci* XVII, 116-127.
- Killgrove, K. and Tykot, R. H. (2013). Food for Rome: A stable isotope investigation of diet in the Imperial period (1st–3rd centuries AD). *Journal of Anthropological Archaeology* 32 (1), 28-38.

- King, C.L., Halcrow, S.E., Millard, A.R., Gröcke, D.R., Standen, V.G., Portilla, M. and Arriaza, B.T. (2018). Let's talk about stress, baby! Infant-feeding practices and stress in the ancient Atacama desert, Northern Chile. *American Journal of Physical Anthropology* 166 (1), 139-155.
- Klales, A. R., Ousley, S. D. and Vollner, J. M. (2012). A revised method of sexing the human innominate using Phenice's nonmetric traits and statistical methods. *American Journal of Physical Anthropology* 149 (1), 104-114.
- Larralde, M., Santos Muñoz, A., Boggio, P., Di Gruccio, V., Weis, I. and Schygiel, A. (2007). Scurvy in a 10-month-old boy. *International journal of dermatology* 46 (2), 194-198.
- Lewis, M. E. (2004). Endocranial lesions in non-adult skeletons: understanding their aetiology. *International Journal of Osteoarchaeology* 14 (2), 82-97.
- Lightfoot, E., Šlaus, M., Šikanjić, P. and O'Connell, T. (2014). Metals and millets: Bronze and Iron Age diet in inland and coastal Croatia seen through stable isotope analysis. *Archaeological and Anthropological Sciences*, 1-12.
- Longin, R. (1971). New method of collagen extraction for radiocarbon dating. *Nature* 230, 241-242.
- Mays, S. (2008a). A likely case of scurvy from early Bronze Age Britain. *International Journal of Osteoarchaeology* 18 (2), 178-187.
- Mays, S. (2008b). Metabolic Bone Disease. In Pinhasi, R. and Mays, S. (editors) *Advances in Human Palaeopathology*. Chichester: Wiley & Sons Ltd.
- Mays, S., Brickley, M. and Ives, R. (2006). Skeletal manifestations of rickets in infants and young children in a historic population from England. *American Journal of Physical Anthropology* 129 (3), 362-374.
- Mekota, A. M., Grupe, G., Ufer, S. and Cuntz, U. (2009). Identifying starvation episodes using stable isotopes in hair. *Rechtsmedizin* 19 (6), 431-440.
- Millard, A. R. (2000). A model for the effect of weaning on nitrogen isotope ratios in humans. In Goodfriend, G., Collins, M., Fogel, M., Macko, S., and Wehmiller, J. (editors) *Perspectives in Amino Acid and Protein Geochemistry*. Oxford: Oxford University Press. 51-59.
- Moorrees, C.F., Fanning, E.A. and Hunt Jr, E.E., (1963). Formation and resorption of three deciduous teeth in children. *American Journal of Physical Anthropology*, 21 (2), 205-213.
- Moore, J. and Koon, H. E. C. (2017). Basilar portion porosity: A pathological lesion possibly associated with infantile scurvy. *International Journal of Paleopathology* 18 (Supplement C), 92-97.
- Munday, K., Fulford, A. and Bates, C.J. (2005). Vitamin C status and collagen cross-link ratios in Gambian children. *British journal of nutrition*, 93 (4), 501-507.
- Murko, M. (2011). *ZAGORJE - Kidričeva ROAD*. The municipality of Zagorje ob Savi. 819/2009 - MP.
- Murray, M. and Schoeninger, M. (1988). Diet, status, and complex social structure in Iron Age Central Europe: some contributions of bone chemistry. In Gibson, D. and Geselowitz, M. (editors) *Tribe and polity in Late Prehistoric Europe*. London: Plenum Press. 155-176.

National Institutes of Health (NIH) Office of Dietary Supplements. (2018) Vitamin C-Fact sheet for health professionals. Retrieved from <https://ods.od.nih.gov/factsheets/VitaminC-HealthProfessional/>

National Research Council (NRC). (1989) Food and Nutrition Board. Water soluble vitamins. In: Recommended Dietary Allowances. (10th Ed). Washington DC: National Academic Press, 115-123.

Nguyen, T. T. H., Lindmark, U. and Bengtson, A. (2013). Knowledge of child nutrition when breastfeeding—A study of mothers living outside Hanoi. *Health* 2013.

Noe-Nygaard, N., Price, T. D. and Hede, S. U. (2005). Diet of aurochs and early cattle in southern Scandinavia: evidence from 15N and 13C stable isotopes. *Journal of Archaeological Science* 32 (6), 855-871.

Nicholls, R. and Koon, H. (2016). The Use of Stable Light Isotopes as a Method of Exploring the Homogeneity and Heterogeneity of Diet in Late Bronze Age and Early Iron Age Temperate Europe: A Preliminary Study. In Armit, I., Potrebica, H., Črešnar, M., Mason, P., and Büster, L. (editors) *Cultural Encounters in Iron Age Europe*. Vol. 38. Budapest: Archaeolingua, 145-164.

Nicholls, R.A. (2017). *More than bones. An investigation of life, death and diet in later prehistoric Slovenia and Croatia* (Doctoral dissertation, University of Bradford).

Olsen, K. C., White, C. D., Longstaffe, F. J., von Heyking, K., McGlynn, G., Grupe, G., & Rühli, F. J. (2014). Intraskkeletal isotopic compositions ($\delta^{13}\text{C}$, $\delta^{15}\text{N}$) of bone collagen: Nonpathological and pathological variation. *American Journal of Physical Anthropology*, 153(4), 598-604.

Ortner, D. J. (2003). Identification of pathological conditions in human skeletal remains. New York: Academic Press.

Ortner, D. J., Butler, W., Cafarella, J. and Milligan, L. (2001). Evidence of probable scurvy in subadults from archeological sites in North America. *American Journal of Physical Anthropology* 114 (4), 343-351.

Ortner, D. J. and Ericksen, M. F. (1997). Bone changes in the human skull probably resulting from scurvy in infancy and childhood. *International Journal of Osteoarchaeology* 7 (3), 212-220.

Ortner, D. J., Kimmerle, E. H. and Diez, M. (1999). Probable evidence of scurvy in subadults from archeological sites in Peru. *American Journal of Physical Anthropology* 108 (3), 321-331.

Ortner, D. J. and Mays, S. (1998). Dry-bone manifestations of rickets in infancy and early childhood. *International Journal of Osteoarchaeology* 8 (1), 45-55.

Phenice, T. W. (1969). A newly developed visual method of sexing the os pubis. *American Journal of Physical Anthropology* 30 (2), 297-301.

Reed, K. and Dmić, I. (2016). Iron Age Diet at Sisak, Croatia: Archaeobotanical Evidence of Foxtail Millet (*Setaria Italica* [L.] P.Beauv.). *Oxford Journal of Archaeology* 35 (4), 359-368.

Reitsema, L.J. (2013). Beyond Diet Reconstruction: Stable Isotope Applications to Human Physiology, Health, and Nutrition. *American Journal of Human Biology*. 25, 445-456.

Reynard, L. M. and Tuross, N. (2015). The known, the unknown and the unknowable: weaning times from archaeological bones using nitrogen isotope ratios. *Journal of Archaeological Science* 53, 618-625.

- Richards, M. (2003) Sharp shift in diet at onset of Neolithic. *Nature. Brief Communications* 425, 366.
- Roberts, C. A., and Manchester, K. (2010). The archaeology of disease (3rd Ed). Stoud: History Press, 168.
- Romek, K. M., Julien, M., Frasset-Darrieux, M., Tea, I., Antheaume, I., Hankard, R. and Robins, R. J. (2013). Human baby hair amino acid natural abundance ¹⁵N-isotope values are not related to the ¹⁵N-isotope values of amino acids in mother's breast milk protein. *Amino Acids* 45 (6), 1365-1372.
- Schattmann, A., Bertrand, B., Vatteoni, S., and Brickley, M. (2016). Approaches to co-occurrence: Scurvy and rickets in infants and young children of 16-18th century Douai, France. *International Journal of Paleopathology* 12, 63-75.
- Salesse, K., Fernandes, R., Rochefort, X., Brůžek, J., Castex, D., Dufour, E. (2018). IsoArch.eu: An open-access and collaborative isotope database for bioarchaeological samples from the Graeco-Roman world and its margins. *Journal of Archaeological Science: Reports*. 19, 1050–1055.
- Salesse, K., Fernandes, R., Rochefort, X., Brůžek, J., Castex, D., Dufour, E. (2019). www.IsoArch.eu (v.1.1), accessed 06/16/2019
- Siegel, B.V (1993). Vitamin C and immune response in health and disease. In Khuzfled, D.M. (ed). *Nutrition and immunology*. New York: Plenum Press, 167-96
- Snoddy, A.M.E., Buckley, H.R., Elliott, G.E., Standen, V.G., Arriaza, B.T. and Halcrow, S.E. (2018). Macroscopic features of scurvy in human skeletal remains: A literature synthesis and diagnostic guide. *American journal of physical anthropology*, 167(4), 876-895.
- Tafari, M. A., Craig, O. E. and Canci, A. (2009) Stable isotope evidence for the consumption of millet and other plants in Bronze Age Italy. *American Journal of Physical Anthropology* 139 (2), 146-153.
- Tecco Hvala, S. (2014), Kačaste fibule z območja Slovenije / Serpentine fibulae from Slovenija. *Arheološki vestnik* 65, 123-186.
- Teržan, B. (1976), Certoška fibula / Die Certosafibel. *Arheološki vestnik* 27, 317-443.
- Thomas, W.R. & Holt P.Z. (1978). Vitamin and immunity: an assessment of evidence. *Clinical Experimental Immunology* 32, 370-79.
- Tieszen, L. L., (1991) Natural variations in the carbon isotope values of plants: Implications for archaeology, ecology, and paleoecology. *Journal of Archaeological Science* 18 (3), 227-248.
- Tsuchiya, H., and Bates, C.J. (2003). Comparison of vitamin C deficiency with food restriction on collagen cross-link ratios in bone, urine and skin of weanling guinea-pigs. *British Journal of Nutrition*, 89 (3), 303-310.
- Tsutaya, T. and Yoneda, M., 2015. Reconstruction of breastfeeding and weaning practices using stable isotope and trace element analyses: A review. *American journal of physical anthropology*, 156, 2-21.
- Tykot, R. H. (2004) Stable isotopes and diet: You are what you eat. In Martini, M., Milazzo, M., and Piacentini, M. (editors) *Physics Methods in Archaeometry*. Vol. 154. Amsterdam: IOS Press. 433-444.
- Van der Merwe, N. J. and Medina, E. (1991) The canopy effect, carbon isotope ratios and foodwebs in amazonia. *Journal of Archaeological Science* 18 (3), 249-259.
- Van-Klinken, G. (1999) Bone Quality Indicators for Paleodietary and Radiocarbon Measurements. *Journal of Archaeological Science* 26, 687-695.

Walker, P. L. (2008) Sexing skulls using discriminant function analysis of visually assessed traits. *American Journal of Physical Anthropology* 136 (1), 39-50.

Walker, P. L., Bathurst, R. R., Richman, R., Gjerdrum, T. and Andrushko, V. A. (2009) The causes of porotic hyperostosis and cribra orbitalia: A reappraisal of the iron-deficiency-anemia hypothesis. *American Journal of Physical Anthropology* 139 (2), 109-125.

Waters-Rist, A. L. and Katzenberg, M. A. (2010) The effect of growth on stable nitrogen isotope ratios in subadult bone collagen. *International Journal of Osteoarchaeology* 20 (2), 172-191.

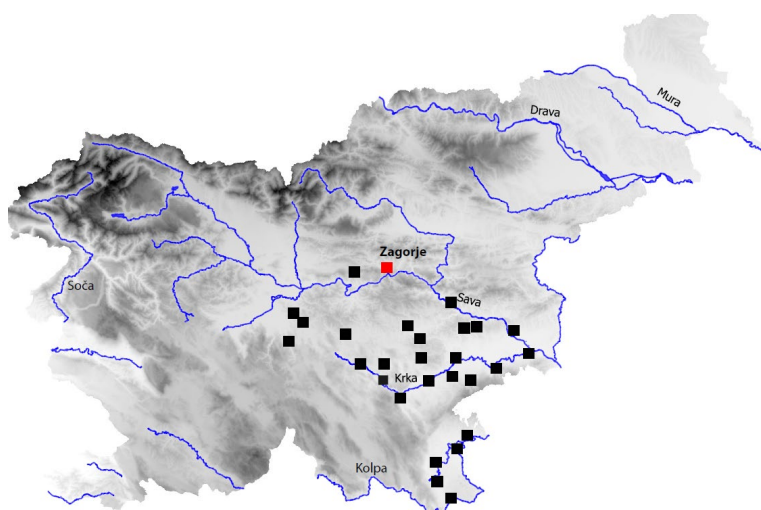
Webb, P. A. O. and Suchey, J. M. (1985) Epiphyseal union of the anterior iliac crest and medial clavicle in a modern multiracial sample of American males and females. *American Journal of Physical Anthropology* 68 (4), 457-466.

Weston, D. A. (2008) Investigating the specificity of periosteal reactions in pathology museum specimens. *American Journal of Physical Anthropology* 137 (1), 48-59.

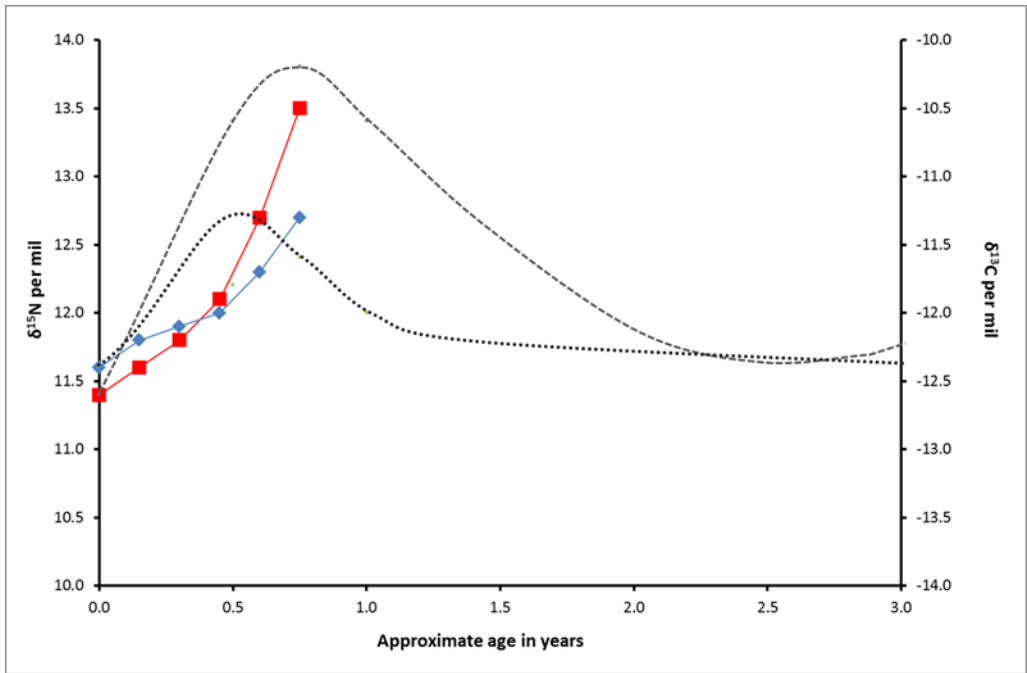
Wijndaele, K., Lakshman, R., Landsbaugh, J. R., Ong, K. K. and Ogilvie, D. (2009) Determinants of Early Weaning and Use of Unmodified Cow's Milk in Infants: A Systematic Review. *Journal of the American Dietetic Association* 109 (12), 2017-2028.

Weinstein, M., Babyn, P., & Zlotkin, S. (2001). An orange a day keeps the doctor away: scurvy in the year 2000. *Pediatrics*, 108(3), e55-e55.

World Health Organisation (2005): Guiding Principles for Feeding Non-Breast-fed Children 6-24 Months of Age (Geneva: World Health Organisation). – (2019): "The WHO Child Growth Standards", available at <http://www.who.int/childgrowth/en/>



Supplementary 1 : Map showing major Early Iron Age centres of the Dolenjska region of Slovenia (Zagorje ob Savi marked in red). Map: N Dolinar, Archive IPCHS.



Supplementary 2 : A schematic model of change in C and N isotope ratios in collagen over time, related to breastfeeding and weaning adapted from King et al (2018) and Millard (2000). The dashed line represents an abrupt increase in $\delta^{15}\text{N}$ values related to the onset of breastfeeding. The dotted line represents the smaller change in $\delta^{13}\text{C}$ values, unless the diet of the mother changes to incorporate/reduce marine or C4 based foods. The incremental dentine data obtained from the Zagorje ob Savi infant presented in figure 5 is also included for comparison ($\delta^{15}\text{N}$ values in red and $\delta^{13}\text{C}$ values in blue).