

bradscholars

Evaluating osteological ageing from digital data

Item Type	Article
Authors	Villa, C.;Buckberry, Jo;Lynnerup, N.
Citation	Villa C, Buckberry J and Lynnerup N (2019) Evaluating osteological ageing from digital data. Journal of Anatomy. 235(2): 386-395.
DOI	https://doi.org/10.1111/joa.12544
Rights	© 2016 Wiley. This is the peer reviewed version of the following article: Villa C, Buckberry J and Lynnerup N (2019) Evaluating osteological ageing from digital data. Journal of Anatomy. 235(2): 386-395, which has been published in final form at http://dx.doi.org/10.1111/joa.12544 . This article may be used for non-commercial purposes in accordance with Wiley Terms and Conditions for Self-Archiving.
Download date	2025-04-22 23:43:42
Link to Item	http://hdl.handle.net/10454/8762

Evaluating osteological ageing from digital data

Chiara Villa¹, Jo Buckberry², Niels Lynnerup¹

¹Laboratory of Biological Anthropology, Department of Forensic Medicine, University of Copenhagen, Denmark;

²Biological Anthropology Research Centre, Archaeological Sciences, University of Bradford, UK;

Correspondence

Chiara Villa, Laboratory of Biological Anthropology, Department of Forensic Medicine, Frederik d. 5.´s Vej 11, University of Copenhagen, DK-2100 Copenhagen O, Denmark. T: +45 35 33 71 60 E: chiara.villa@sund.ku.dk

Short running page heading: osteological ageing from digital data

Summary

Age at death estimation of human skeletal remains is one of the key issues in constructing a biological profile both in forensic and archaeological contexts. The traditional adult osteological methods evaluate macroscopically the morphological changes that occur with increasing age of specific skeletal indicators, such as the cranial sutures, the pubic bone, the auricular surface of the ilium and the sternal end of the ribs. Technologies such as CT and laser scanning are becoming more widely used in anthropology, and several new methods have been developed. This review focuses on how the osteological age-related changes have been evaluated in digital data. Firstly, the 3D virtual copies of the bones have been used to mimic the appearance of the dry bones and the application of the traditional methods. Secondly, the information directly extrapolated from CT scan has been used to qualitatively or quantitatively assess the changes of the trabecular bones, the thickness of the cortical bones, and to perform morphometric analyses. Lastly, the most innovative approach has been the mathematical quantification of the changes of the pelvic joints, calculating the complexity of the surface. The importance of new updated reference datasets, created thanks to the use of CT scanning in forensic settings, is also discussed.

Keywords: CT scans, surface scans, trabecular bone, 3D models, curvature

Introduction

The last decades have seen the introduction of 3D technologies to the field of biological and forensic anthropology. Surface scanners (laser or structured light scanners) have been introduced in many laboratories and computed tomography (CT) scanners, even micro-CT scanners, have started to be used for anthropological analysis. These 3D technologies play an important role in permanent documentation of bones, creating virtual copies always accessible even when the actual specimen can no longer be analysed for reasons such as repatriation or reburial. Moreover, virtual osteological collections allow easier and faster sharing of data among researchers around the world, thus promoting comparative studies. Another valid reason for scanning skeletal collections is to preserve bones from further damage and, at the same time, to make those unique and fragile specimens usable for teaching again. Some remarkable examples of digital collections are the “3D collection” of the Smithsonian Institution (humanorigins.si.edu/evidence/3d-collection), “Digitised Diseases” (www.digitiseddiseases.org) and “From Cemetery to Clinic” (www.barc.brad.ac.uk/FromCemeterytoClinic/index.php) of the University of Bradford. There are digital databases also for mummies: e.g., the IMPACT Radiological Mummy Database, designed by Nelson and Wade (www.impactdb.uwo.ca). Lastly, it should be mentioned that many forensic institutes routinely perform CT scanning before autopsy; this generates huge updated datasets of modern populations (Thali et al. 2003; Poulsen and Simonsen 2007).

Digital data have also become increasingly important in dealing with anthropological issues in forensic, biological and archaeological contexts. For examples, CT scans are often used for forensic identification: to compare ante- and post-mortem information, to reconstruct biological profiles, and to evaluate lesions and diseases (for more details see Dedouit et al. 2014). In the same context, laser scanners have been utilised for facial identification (Lynnerup et al. 2009; Cattaneo et al. 2012), for assessing sexual dimorphism, population and ancestry variation (Sholts et al. 2011; Ruiz Mediavilla et al. 2012; Shearer et al. 2012; Sholts and Warmlander 2012). CT has also been recognized as an efficient tool for non-destructive study of archaeological samples, such as mummies and bog bodies (Rühli et al. 2004; Adams and Alsop 2008; Lynnerup 2008), skeletons (Knusel et al. 2013), and even for cremated remains (Minozzi et al. 2010; Harvig et al. 2012). In addition, 3D models created using such technologies facilitate morphometric analysis allowing an objective evaluation of 3D morphological variations of the bones in modern humans, their ancestors, and their closest relatives (Zollikofer and Ponce de Leon 2005; Weber and Bookstein 2011; Weber 2015).

This review will focus on how the morphological skeletal characteristics commonly used in adult age estimation methods have been evaluated from digital data (odontological methods will not be reviewed in this paper). Essentially three approaches have been explored: 1) the use of 3D segmentation to mimic dry bone and the application of traditional methods; 2) the direct assessment of CT image information, looking at the trabecular structure, the thickness of the cortical bones, and/or 2D morphometric analysis; 3) the application of mathematical methods on 3D models, e.g. for quantifying the roughness of the surface. The importance of new updated reference datasets, created thanks to the use of CT scanning in forensic settings, will also be highlighted.

I- the use of 3D segmentation to mimic the appearance of dry bone

Most methods for age estimation in adults focus on the macroscopic and morphological changes of the joint surfaces, such as the pubic symphyseal face (Brooks and Suchey 1990), the auricular surface of the ilium (Lovejoy et al. 1985; Buckberry and Chamberlain 2002), the sternal end of the ribs (İşcan et al. 1984) and cranial sutures (Meindl and Lovejoy 1985). 3D visualisation of bones can be generated from CT images using post-processing software such as 3D slicer, Mimics, Osirix or Amira. The obtained 3D virtual bones have been used to mimic dry bone and the application of traditional methods. First examples of this application can be seen in mummy studies (Lynnerup et al. 2007; Dedouit et al. 2010; Villa et al. 2011); in these specimens, the actual bones cannot be directly assessed but 3D visualizations of the bones can be easily created and used for biological anthropological analyses. However, the performance of the unmodified traditional age estimation methods on 3D models is unclear, since the results of several studies are contradictory.

The method of Suchey-Brooks has been tested on 3D visualizations of dry bones, cadavers and living subjects. Firstly, Telmon et al. (2005) tested the method on a mix sample of dry bones and pubic bones with soft tissues. Their results, albeit based on only two observers, were very promising; they obtained high intra and inter-observer agreement. Dedouit and colleagues also did not report any problems in two forensic cases (Dedouit et al. 2007a; Dedouit et al. 2007b). Conversely, Grabherr et al. (2009), Villa et al. (2013a), Wink (2014) found some difficulty in applying the method of Suchey-Brooks unmodified. Only few diagnostic features could be evaluated in 3D visualization: for instance, the billowing – useful for determination among the first phases – could not clearly be seen in 3D of the living, because the visualisation software was not able to remove all of the soft tissues (Wink 2014); ventral rampart and depth of depression could not be

consistently assessed (Villa et al. 2013a). Wink (2014) created a table of features useful to discern among the phases, listing very few of the diagnostic features of the original method. Further, Grabherr et al. (2009) and Villa et al. (2013a) highlighted the importance of the experience in evaluating digital images and the importance of using correct scanning parameters for obtaining an accurate 3D model. Finally, the studies (Villa et al. 2013a; Wink 2014) also reported a greater variability among the observers than those found in Telmon and colleagues' study.

The evaluation of the 3D auricular surface seems a more difficult task with the traditional methods. Neither the methods of Lovejoy et al. (1985) nor Buckberry and Chamberlain (2002) could be applied unmodified (Barrier et al. 2009; Villa et al. 2013a). The observers of both studies were unable to properly evaluate microporosity and texture. Even macroporosity, transverse organization, apical changes were problematic features and could not be consistently scored. The CT-scanner settings are important here even more because slice thickness, slice increment and pitch can influence the visualization in 3D of the small holes and artefacts can hide the transverse organization (Fig.1). Above all, this surface cannot be easily isolated when soft tissues are present at the time of the CT scanning.

The method of Işcan and Loth (1984) used for evaluating the sternal end of the 4th rib was tested once and excellent agreement between bones and 3D models was found (Dedouit et al. 2008). The sample was composed of 'ribs with soft tissues'. As reported by the authors, one of the main advantages of using 3D visualization was the possibility of assessing fragile calcifications and osteophytes that could be damaged during the maceration process. However, other studies are necessary to yield more confidence in the applicability of this method.

The method of Meindl and Lovejoy (1985) has not been applied unmodified. In many cases, the resolution of the CT scans does not allow proper evaluation of the degree of closure of the sutures on 3D visualisations (Fig. 2); however, CT images permit the evaluation of the degree of closure of the suture in its entirety, looking at both ectocranial and endocranial sutures, as shown by Harth et al. (2010), Chiba et al. (2013), and Boyd et al. (2015).

One study tested two traditional methods (Suchey-Brooks and Buckberry-Chamberlain), applied to 3D models of bones created from laser scans (Villa et al. 2013a). The morphological features of the bone surface were better replicated in laser scans than in CT scans (Fig. 3), however, the problems and results did not differ from those found for 3D models created from CT scans.

Traditional methods of age estimation were developed and calibrated on dry bones, thus it is not surprising that they did not perform particularly well on virtual bones. Digital data have different potential: CT scans should be used to explore the sub surface features, e.g. trabecular bone; 3D models generated from surface scans could be analysed using mathematical approaches, for example, analysing the curvature of the surface. These new approaches and methods will be presented in the next paragraphs.

II. the direct assessment of CT image information

CT data allow evaluation of more information than just the visualization of macroscopic bone surfaces. It is possible to look at what happens below the surface, e.g. to trabecular bone, and to perform morphometric analysis.

It has been shown using X-rays that the bone density decreases with increasing age, the trabecular structures lose their interconnection until they disappear and the medullar space increases. The pubic bone was analysed by Todd (1930), humerus and femur by Schranz (1959), Singh et al. (1970), and Acsádi and Nemeskéri (1970), and the clavicle and calcaneus by Walker and Lovejoy (1985). The changes of the trabecular bone of living subjects were also evaluated using femora with good results (Lynnerup et al. 1990). CT scanning was used for the first time with the same purpose by Pasquier et al. in 1999 to assess the trabecular architecture of the pubic bone. Ten years later other researchers proposed similar approaches using the pubic bone (Wade et al. 2011; Villa et al. 2013b; Lottering et al. 2014; Lopez-Alcaraz et al. 2015) and on other bones. The auricular surface was investigated by Barrier et al. (2009) and Villa et al. (2013b), and the proximal epiphysis of the humerus and the femur by de Froidmont et al. (2013). All the studies demonstrated the effectiveness of CT scans for evaluating trabecular bone changes, but the results are difficult to compare, since different types of sample were used and different methodologies were applied. Most investigators evaluated the changes of trabecular architecture in bones; only Villa et al (2013b) and Lopez-Alcaraz et al. (2015) used CT scan of bodies, dead and living, respectively. It should be considered that the appearance of trabecular bone is different in post-mortem or clinical CT scans when the soft tissues are still in place in comparison with bones: the fine trabecular structure cannot be seen clearly and many of the features measured in CT-scanned bones cannot be evaluated. In addition, the visualisation of the trabecular structures depends on the acquisition protocols (Fig. 4). Not all the authors took advantage of the digital nature of the CT data. Barrier et al. (2009), Villa et al (2013), and de Froidmont et al. (2013) applied only qualitative, visual methodologies, recording

stages of trabecular bone changes. However, very good results were obtained, demonstrating the superiority of CT versus X-rays (de Froidmont et al. 2013) and achieving very high correlation between age at death and trabecular changes (Villa et al. 2013). Quantitative analysis was carried out by Wade et al. (2011), who did not improve the precision of age estimation, but in some way demonstrated that it is possible to reduce the subjectivity of the operator. Image analysis was performed by Pasquier et al. in (1999) and, more recently, by Lopez-Alcaraz et al. (2015), quantifying the change of the grey-level distribution of trabecular bone. Although evaluated in only one study (Lottering et al. 2014), there seems to be great potential in looking at cortical width, especially in males.

Another way to quantify age-related changes in bone is through morphometric analysis. Ferrant (2009), Lottering et al. (2014) and Chiba et al. (2014) measured angles, area, circumference, distance, height and width in both 3D models and CT images. Once again, the object of the research was the pelvic bone. Ferrant et al. (2009) considered angle, height and length in acetabulum, symphyseal and auricular surfaces but the correlation of their variables with age was very low. Lottering and colleagues (2014) found that the overall dimensions of the pubic bone increased with age, and circumference, surface area, height and width were significantly greater over 55 years. Moderate correlations were found by Chiba et al. (2014) for some of the 10 measurements assessed on the pubic symphysis but from their scatterplots highly individual variation is evident, particularly after 20-30 years. However, these studies are important because they have again shown the possibility of using repeatable variables and quantitative methods for age estimation, reducing the operator subjectivity.

III. the application of mathematical methods on 3D models

3D morphological variations of the pelvic bones have been explored using mathematical approaches. Only a few studies can be cited: Biwasaka et al. (2013), Villa et al. (2015a), Slice and Algee-Hewitt (2015), and Stoyanova et al. (2015) .

The first two studies - Biwasaka et al. (2013) and Villa et al. (2015a) - mathematically quantified the observable morphological changes used for age estimation of the pubic bone (both studies) and the auricular surface (only Villa et al. 2015a), calculating the curvature of the surface. In this context, the curvature can be defined as the variation of the surface from being flat; concavity results in negative values of curvature, convexity in positive ones. The pelvic joint surfaces are subject to morphological and degenerative changes with increasing age; the

surface is initially dominated by high ridges and well-marked grooves, or by marked transverse organisation; as age progresses, the surface becomes smoother and flatter, evolving, finally, to an irregular surface with increasing porosity and depressions. Mathematically, this means the surface is strongly convex and concave, with high positive and negative curvature values in the first stages / phases, changing to a flat surface in middle age with lower and more homogenous curvature values; lastly, the old irregular surface corresponds to less homogenous curvature values with, primarily, negative values due to concavities. It has been shown that curvature analysis applied on recording kits (Suchey-Brooks pubic bone casts (Fig. 5) and the “auricular surface recording kit” for the Buckberry–Chamberlain method) resulted in highly significant correlations between age and curvature (Villa et al. 2015a), while the same approach on bones from Terry Collection (Villa et al. 2015a) or contemporary Japanese sample (Biwasaka et al., 2013) gave less clear signals. Concerning the pubic bones, the curvatures of phases I and II could be well differentiated from those of the other phases, but after phase III the curvature signals became indistinct for all age / phases. Lower correlations associated with large individuals were found for the auricular surface. These two papers certainly do not provide a perfect solution to estimate age at death, but provide the base for future developments; the authors have just started dealing with a very small part of differential geometry. As claimed by Villa et al. (2015a), further surface properties such as spatial frequency and directional orientation should be investigated

Slice and colleagues (Slice and Algee-Hewitt 2015 and Stoyanova et al. 2015) applied morphological approaches to study the variation of the surface of the pubic symphysis obtained from laser scanning. The two studies are part of the same larger project that aims to develop fully quantitative methods for age-at-death- estimation standardizing the procedures. Pubic bones of white males from the W.M. Bass Skeletal collection were laser scanned and used in the studies. 3D coordinates of the 3D models were transformed using spatial principal component analysis (PCA) such as the first principal component and second principal component accounting for the most variance approximated the plane of the pubic symphysis (x and y-axes) with its associated surface irregularity aligned with the third principal component (z-axis). The third principal component was used as a quantitative indicator of the complexity of the surface. Slice and Algee-Hewitt (2015) evaluated the complexity of the surface using a variance-based score, while Stoyanova et al. (2015) used thin plate spline algorithm. Similar to the results reported for the curvature, better discrimination could be obtained in the first phases (Suchey- Brooks phases 1-3); shape variations in the older surface (Suchey- Brooks phases 4-6) were more difficult to evaluate.

These four papers have explored the possibility of a objective quantitative approach rather than the more traditional subjective / visual way, demonstrating that comparable, if not better, result can be obtained. However, we should not forget that reproducibility of the quantitative analysis among instruments should be tested, since the performance parameters of each laser scanner and the scanning setting of the CT scanner may influence the mathematical outcome of the 3D models (Villa et al. 2015b; Algee-Hewitt and Wheat 2016).

Reference Datasets

Adjunct to the much wider application of CT scanning in forensic anthropology is the noteworthy fact that this may also be a basis for obtaining more reference data. Most of the existing age estimation methods were developed using the Terry Collection (Smithsonian Institution) or W.M. Bass Skeletal Collection (University of Tennessee). CT scanning before autopsy has become routinely in many forensic departments (Thali et al. 2003; Leth 2007; Poulsen and Simonsen 2007; Rutty et al. 2008) with the great advantage of creating modern, up-to-date virtual collections. An example is the “Skeletal Biology and Forensic Anthropology Virtual Osteological Database” housed at the Queensland University of Technology, a CT-scan dataset of modern Australian male and female individuals aged birth to 75 years (Lottering et al. 2014). These virtual anthropological collections can be used to test and improve the traditional methods, and to develop and calibrate new methodologies. In addition, the existence of comparative skeletal collections is important, not least as access to larger samples may, for example, result in more data on age-related change, which may give a better so-called “coverage” of a given method (see, e.g., Konigsberg et al., 2008). Most often, the dry-bone methods discussed above were developed on specific anatomical collections creating the well-known problem of ‘age mimicry’, (Bocquet-Appel and Masset 1982). Also, the collections often reflect bony changes in humans living more than 100 years ago, raising the question of whether they are completely applicable to modern forensic cases. A recent estimation procedure that accounts for these problems is the Transition Analysis: it is a Bayesian statistical approach that allows combining likelihood curves for different skeletal indicators (a range of features of the cranial sutures, pubic bone and auricular surface) to obtain an overall age estimation (Boldsen et al. 2002) using a prior distribution. This method enables age estimates even in case of fragmentary information, and age interval and maximum likelihood estimated are calculated ad hoc, i.e. they are based on the specific information available and they change from one skeleton to the next. It could be worth integrating the results of new methods

developed using digital data in the statistical procedure of transition analysis or other Bayesian approaches, so that age estimates including appropriate 95% prediction intervals could be calculated. Moreover, the digital information extracted from CT and laser scanning data may allow testing different mathematical and statistical metric models to better assess the relation among the different traits and to help in making anthropological methods more uniform in their application.

Concluding remarks and future directions

Age estimation of human skeletal remains is one of the most important steps in constructing a biological profile both in archaeological and forensic contexts. The traditional adult osteological methods are based on the macroscopic evaluation of the changes of surface features that occur with increasing age of specific skeletal indicators, such as the cranial suture, the pubic bone, the auricular surface of the ilium and the sternal end of the ribs. Since technologies such as CT and laser scanning are becoming more widely used in anthropology, a review of how the osteological age-related changes have been evaluated in digital data is opportune.

Initially, 3D virtual copies of bones have been used to apply the traditional adult age estimation methods. However, most of the osteological features, such as texture or porosity, could not be assessed properly. The methods developed and calibrated on dry bones do not perform equally well on digital bones; their accuracy decreases and not only the experience of the observer but also the CT / laser scanner setting have an influence on how the diagnostic features can be seen.

The next step has been to take advantage of the digital nature of the data of CT and surface scanning: new skeletal indicators have been considered and new quantitative methodologies have been applied. Trabecular bone changes and cortical bone width, as assessed from CT images, have been demonstrated to be useful anatomical structures for age estimation. However, their changes have been expressed only in a qualitative way, as seen for traditional methods. Only two studies have quantitatively analysed the changes using the grey-scale variation of the CT images. Trabecular bone changes could be also investigated using the variation of the Hounsfield Units, and cortical thickness could be mathematically quantified: for instance, femoral cortical thickness has been quantified to evaluate the risk of hip fracture in patients with osteoporosis (Poole et al. 2012; Treece et al. 2012). Similar procedures could be applied to assess the thickness variation associated with increasing age.

A step forward towards quantitative methods is the mathematical analysis of 3D models from CT and laser scanning. The most innovative approach has been the geometrical quantification of the changes of the pelvic joints, calculating the curvature of the surface or applying thin plate spline algorithm. The results are interesting and there is clearly room for improvement. To further develop these methods, a close collaboration between anthropologists, mathematicians, statisticians and computer engineers will be beneficial. Another possibility may be the application of landmark-based geometric morphometrics. This approach has been extensively used in anthropology to assess sexual dimorphism on 3D models of crania, coxal bones and femora (Hennessy et al. 2005; Bilfeld et al. 2012; Franklin et al. 2012; Bilfeld et al. 2013; Morgan et al. 2013; Cho et al. 2015; Cavaignac et al. 2016; Chovalopoulou et al. 2016; Duquesnel Mana et al. 2016), to investigate population variation (Hennessy and Stringer 2002; Cho et al. 2015; Galland and Friess 2016; Lesciotto et al. 2016) but not yet to estimate age-at-death.

As for traditional methods, studies have primarily focused on the pelvic bone. A much wider array of skeletal bones and features should be taken into consideration. Indeed, many anthropologists suggest that the combination of as many skeletal indicators as possible would improve the accuracy of age estimation, since each skeletal trait may be subjected to different influences and expresses biological age differently (Ubelaker 2000). All skeletal features, even those that are normally overlooked such as the enthesal changes of all the bones (Nolte and Wilczak 2013), and the alteration of the vertebrae and of the sacrum (Rühli et al. 2005; Belcastro et al. 2008), can contribute to reach an accurate age estimation. Milner and Boldsen (2012) were able to estimate ages at death more accurately by just looking at features of the entire skeleton than was achievable using any of the traditional methods.

Another digital technology that should be considered for estimating age in adults is the magnetic resonance (MR). Combination of the information of CT and MR may help to narrow age estimation intervals that are very wide especially in older individuals. Traditional methods consider the morphological changes of the bones surfaces; using MR it would be possible to look at the cartilage. For example, cranial sutures have been assessed using MR images (Cotton et al. 2005). However, at present this technology is time consuming and its availability is limited; only few forensic institutes own one, such as in Copenhagen or in Zurich.

In conclusion, modern reference collections should be used to calibrate existing and future methods, to develop quantitative unbiased age estimation methods, avoiding the well-known

problem of ‘age mimicry’. Furthermore, use of 3D models obtained from these reference collections can be used to 3D print population-specific casts.

Acknowledgements

CV was supported from the Danish Council for Independent Research (DFR – 4005-00102B – FTP)

References

- Acsádi G, Nemeskéri J** (1970) *History of Human Life Span and Mortality.*, Akadémiai Kiadó, Budapest
- Adams JE, Alsop CW** (2008) Imaging in Egyptian mummies. In *Egyptian Mummies and Modern Science* (ed David R), pp. 21-42. Cambridge: Cambridge University Press.
- Algee-Hewitt BF, Wheat AD** (2016) The reality of virtual anthropology: Comparing digitizer and laser scan data collection methods for the quantitative assessment of the cranium. *Am J Phys Anthropol* **160**, 148-155.
- Barrier P, Dedouit F, Braga J, et al.** (2009) Age at death estimation using multislice computed tomography reconstructions of the posterior pelvis. *J Forensic Sci* **54**, 773-778.
- Belcastro MG, Rastelli E, Mariotti V** (2008) Variation of the degree of sacral vertebral body fusion in adulthood in two European modern skeletal collections. *Am J Phys Anthropol* **135**, 149-160.
- Bilfeld MF, Dedouit F, Rousseau H, et al.** (2012) Human coxal bone sexual dimorphism and multislice computed tomography: geometric morphometric analysis of 65 adults. *J Forensic Sci* **57**, 578-588.
- Bilfeld MF, Dedouit F, Sans N, Rousseau H, Rouge D, Telmon N** (2013) Ontogeny of size and shape sexual dimorphism in the ilium: a multislice computed tomography study by geometric morphometry. *J Forensic Sci* **58**, 303-310.
- Biwasaka H, Sato K, Aoki Y, et al.** (2013) Three dimensional surface analyses of pubic symphyseal faces of contemporary Japanese reconstructed with 3D digitized scanner. *Legal Medicine* **15**, 264-268.
- Bocquet-Appel JP, Masset C** (1982) Farewell to Paleodemography. *Journal of Human Evolution* **11**, 321-333.
- Boldsen JL, Milner GR, Konigsberg LW, Wood JW** (2002) Transition analysis: a new method for estimating age from skeletons. In *Paleodemography : Age Distributions from Skeletal Samples* (eds Hoppa RD, Vaupel JW), pp. 73-106. New York: Cambridge University Press
- Boyd KL, Villa C, Lynnerup N** (2015) The Use of CT Scans in Estimating Age at Death by Examining the Extent of Ectocranial Suture Closure. *J Forensic Sci* **60**, 363-369.
- Brooks S, Suchey J** (1990) Skeletal age determination based on the os pubis: a comparison of the Acsadi-Nemeskeri and Suchey-Brooks methods. *Human Evolution* **5**, 227-238.
- Buckberry JL, Chamberlain AT** (2002) Age estimation from the auricular surface of the ilium: A revised method. *American Journal of Physical Anthropology* **119**, 231-239.
- Cattaneo C, Cantatore A, Ciaffi R, et al.** (2012) Personal identification by the comparison of facial profiles: testing the reliability of a high-resolution 3D-2D comparison model. *J Forensic Sci* **57**, 182-187.
- Cavaignac E, Savall F, Faruch M, Reina N, Chiron P, Telmon N** (2016) Geometric morphometric analysis reveals sexual dimorphism in the distal femur. *Forensic Science International* **259**.
- Chiba F, Makino Y, Motomura A, et al.** (2014) Age estimation by quantitative features of pubic symphysis using multidetector computed tomography. *Int J Legal Med* **128**, 667-673.
- Chiba F, Makino Y, Motomura A, et al.** (2013) Age estimation by multidetector CT images of the sagittal suture. *Int J Legal Med* **127**, 1005-1011.
- Cho HJ, Kwak DS, Kim IB** (2015) Morphometric Evaluation of Korean Femurs by Geometric Computation: Comparisons of the Sex and the Population. *Biomed Res Int* **2015**, 730538.

- Chovalopoulou ME, Valakos ED, Manolis SK** (2016) Sex determination by three-dimensional geometric morphometrics of the vault and midsagittal curve of the neurocranium in a modern Greek population sample. *Homo*.
- Cotton F, Rozzi FR, Vallee B, et al.** (2005) Cranial sutures and craniometric points detected on MRI. *Surg Radiol Anat* **27**, 64-70.
- de Froidmont S, Grabherr S, Vaucher P, et al.** (2013) Virtual anthropology: a comparison between the performance of conventional X-ray and MDCT in investigating the trabecular structure of long bones. *Forensic Sci Int* **225**, 53-59.
- Dedouit F, Bindel S, Gainza D, et al.** (2008) Application of the Iscan method to two- and three-dimensional imaging of the sternal end of the right fourth rib. *J Forensic Sci* **53**, 288-295.
- Dedouit F, Geraut A, Baranov V, et al.** (2010) Virtual and macroscopical studies of mummies-Differences or complementarity? Report of a natural frozen Siberian mummy. *Forensic Science International* **200**.
- Dedouit F, Savall F, Mokrane FZ, et al.** (2014) Virtual anthropology and forensic identification using multidetector CT. *Br J Radiol* **87**, 20130468.
- Dedouit F, Telmon N, Costagliola R, Otal P, Joffre F, Rouge D** (2007a) Virtual anthropology and forensic identification: Report of one case. *Forensic Science International* **173**, 182-187.
- Dedouit F, Telmon N, Guilbeau-Frugier C, et al.** (2007b) Virtual autopsy and forensic identification-practical application: A report of one case. *Journal of Forensic Sciences* **52**, 960-964.
- Duquesnel Mana M, Adalian P, Lynnerup N** (2016) Lateral angle and cranial base sexual dimorphism: a morphometric evaluation using computerised tomography scans of a modern documented autopsy population from Denmark. *Anthropol Anz*.
- Ferrant O, Rouge-Maillart C, Guittet L, et al.** (2009) Age at death estimation of adult males using coxal bone and CT scan: a preliminary study. *Forensic Sci Int* **186**, 14-21.
- Franklin D, Cardini A, Flavel A, Kuliukas A** (2012) The application of traditional and geometric morphometric analyses for forensic quantification of sexual dimorphism: preliminary investigations in a Western Australian population. *International Journal of Legal Medicine* **126**, 549-558.
- Galland M, Friess M** (2016) A three-dimensional geometric morphometrics view of the cranial shape variation and population history in the New World. *Am J Hum Biol*.
- Grabherr S, Cooper C, Ulrich-Bochsler S, et al.** (2009) Estimation of sex and age of "virtual skeletons"--a feasibility study. *Eur Radiol* **19**, 419-429.
- Harth S, Obert M, Ramsthaler F, Reuss C, Traupe H, Verhoff MA** (2010) Ossification degrees of cranial sutures determined with flat-panel computed tomography: narrowing the age estimate with extrema. *J Forensic Sci* **55**, 690-694.
- Harvig L, Lynnerup N, Ebsen JA** (2012) Computed Tomography and Computed Radiography of Late Bronze Age Cremation Urns from Denmark: An Interdisciplinary Attempt to Develop Methods Applied in Bioarchaeological Cremation Research. *Archaeometry* **54**, 369-387.
- Hennessy RJ, McLearie S, Kinsella A, Waddington JL** (2005) Facial surface analysis by 3D laser scanning and geometric morphometrics in relation to sexual dimorphism in cerebral--craniofacial morphogenesis and cognitive function. *J Anat* **207**, 283-295.
- Hennessy RJ, Stringer CB** (2002) Geometric morphometric study of the regional variation of modern human craniofacial form. *Am J Phys Anthropol* **117**, 37-48.
- İşcan MY, Loth SR, Wright RK** (1984) Metamorphosis at the Sternal Rib End - a New Method to Estimate Age at Death in White Males. *American Journal of Physical Anthropology* **65**, 147-156.
- Knusel CJ, Wastling V, Ogden AR, Lynnerup N** (2013) The physical analysis of Gristhorpe man: a bronze age osteobiography. In *Gristhorpe Man. A Life and Death in the Bronze Age* (eds Melton ND, Montgomery J, Knusel CJ), pp. 96-115. Oxford, UK: Oxbow books.
- Konigsberg LW, Herrmann NP, Wescott DJ, Kimmerle EH** (2008) Estimation and evidence in forensic anthropology: Age-at-death. *Journal of Forensic Sciences* **53**, 541-557.
- Lesciotta KM, Cabo LL, Garvin HM** (2016) A morphometric analysis of prognathism and evaluation of the gnathic index in modern humans. *Homo*.

- Leth PM** (2007) The use of CT scanning in forensic autopsy. *Forensic Sci Med Pathol* **3**, 65-69.
- Lopez-Alcaraz M, Gonzalez PM, Aguilera IA, Lopez MB** (2015) Image analysis of pubic bone for age estimation in a computed tomography sample. *Int J Legal Med* **129**, 335-346.
- Lottering N, Reynolds MS, MacGregor DM, Meredith M, Gregory LS** (2014) Morphometric modelling of ageing in the human pubic symphysis: sexual dimorphism in an Australian population. *Forensic Sci Int* **236**, 195 e191-111.
- Lovejoy CO, Meindl RS, Pryzbeck TR, Mensforth RP** (1985) Chronological metamorphosis of the auricular surface of the ilium: a new method for the determination of adult skeletal age at death. *Am J Phys Anthropol* **68**, 15-28.
- Lynnerup N** (2008) Computed tomography scanning and three-dimensional visualization of mummies and bog bodies. In *Advances in Human Paleopathology* (eds Pinhasi R, Mays S), pp. 101-120. Chichester: John Wiley & Sons Ltd.
- Lynnerup N, Clausen ML, Kristoffersen AM, Steglich-Arnholm H** (2009) Facial recognition and laser surface scan: a pilot study. *Forensic Sci Med Pathol* **5**, 167-173.
- Lynnerup N, Jurik AG, Dalstra M** (2007) CT scanning, 3D visualization and stereolithography. In *Grauballe Man. Iron age bog body revisited* (eds Asingh P, Lynnerup N), pp. 111-123. Moesgård: Jutland, Archaeological Society.
- Lynnerup N, Thomsen I, Frohlich B** (1990) A non-invasive technique for age at death determination. *Med Sci Law* **30**, 317-320.
- Meindl RS, Lovejoy CO** (1985) Ectocranial suture closure: a revised method for the determination of skeletal age at death based on the lateral-anterior sutures. *Am J Phys Anthropol* **68**, 57-66.
- Milner GR, Boldsen JL** (2012) Skeletal Age Estimation: Where We Are and Where We Should Go. In *A Companion to Forensic Anthropology*, pp. 224-238. John Wiley & Sons, Ltd.
- Minozzi S, Giuffra V, Bagnoli J, et al.** (2010) An investigation of Etruscan cremations by Computed Tomography (CT). *Antiquity* **84**, 195-201.
- Morgan J, Lynnerup N, Hoppa RD** (2013) The lateral angle revisited: a validation study of the reliability of the lateral angle method for sex determination using computed tomography (CT). *J Forensic Sci* **58**, 443-447.
- Nolte M, Wilczak C** (2013) Three-dimensional Surface Area of the Distal Biceps Enthesis, Relationship to Body Size, Sex, Age and Secular Changes in a 20th Century American Sample. *International Journal of Osteoarchaeology* **23**, 163-174.
- Pasquier E, De Saint Martin Pernot L, Burdin V, et al.** (1999) Determination of age at death: assessment of an algorithm of age prediction using numerical three-dimensional CT data from pubic bones. *Am J Phys Anthropol* **108**, 261-268.
- Poole KES, Treece GM, Mayhew PM, et al.** (2012) Cortical Thickness Mapping to Identify Focal Osteoporosis in Patients with Hip Fracture. *Plos One* **7**.
- Poulsen K, Simonsen J** (2007) Computed tomography as routine in connection with medico-legal autopsies. *Forensic Science International* **171**, 190-197.
- Ruiz Mediavilla E, Perea Perez B, Labajo Gonzalez E, Sanchez Sanchez JA, Santiago Saez A, Dorado Fernandez E** (2012) Determining sex by bone volume from 3D images: discriminating analysis of the tali and radii in a contemporary Spanish reference collection. *Int J Legal Med* **126**, 623-631.
- Rutty GN, Morgan B, O'Donnell C, Leth PM, Thali M** (2008) Forensic institutes across the world place CT or MRI scanners or both into their mortuaries. *J Trauma* **65**, 493-494.
- Rühli FJ, Chhem RK, Boni T** (2004) Diagnostic paleoradiology of mummified tissue: interpretation and pitfalls. *Can Assoc Radiol J* **55**, 218-227.
- Rühli FJ, Muntener M, Henneberg M** (2005) Age-dependent changes of the normal human spine during adulthood. *Am J Hum Biol* **17**, 460-469.
- Schranz D** (1959) Age-Determination from the Internal Structure of the Humerus. *American Journal of Physical Anthropology* **17**, 273-277.

- Shearer BM, Sholts SB, Garvin HM, Warmlander SK** (2012) Sexual dimorphism in human browridge volume measured from 3D models of dry crania: a new digital morphometrics approach. *Forensic Sci Int* **222**, 400 e401-405.
- Sholts SB, Walker PL, Kuzminsky SC, Miller KW, Warmlander SK** (2011) Identification of group affinity from cross-sectional contours of the human midfacial skeleton using digital morphometrics and 3D laser scanning technology. *J Forensic Sci* **56**, 333-338.
- Sholts SB, Warmlander SK** (2012) Zygomaticomaxillary suture shape analyzed with digital morphometrics: reassessing patterns of variation in American Indian and European populations. *Forensic Sci Int* **217**, 234 e231-236.
- Singh M, Nagrath AR, Maini PS** (1970) Changes in trabecular pattern of the upper end of the femur as an index of osteoporosis. *J Bone Joint Surg Am* **52**, 457-467.
- Slice DE, Algee-Hewitt BF** (2015) Modeling Bone Surface Morphology: A Fully Quantitative Method for Age-at-Death Estimation Using the Pubic Symphysis. *J Forensic Sci* **60**, 835-843.
- Stoyanova D, Algee-Hewitt BF, Slice DE** (2015) An enhanced computational method for age-at-death estimation based on the pubic symphysis using 3D laser scans and thin plate splines. *Am J Phys Anthropol* **158**, 431-440.
- Telmon N, Gaston A, Chemla P, Blanc A, Joffre F, Rouge D** (2005) Application of the Suchey-Brooks method to three-dimensional imaging of the pubic symphysis. *J Forensic Sci* **50**, 507-512.
- Thali MJ, Yen K, Schweitzer W, et al.** (2003) Virtopsy, a new imaging horizon in forensic pathology: virtual autopsy by postmortem multislice computed tomography (MSCT) and magnetic resonance imaging (MRI)--a feasibility study. *J Forensic Sci* **48**, 386-403.
- Todd TW** (1930) Age Changes in the Pubic Bone VIII. Roentgenographic Differentiation. *American Journal of Physical Anthropology* **14**, 255-271.
- Treece GM, Poole KES, Gee AH** (2012) Imaging the femoral cortex: Thickness, density and mass from clinical CT. *Medical Image Analysis* **16**, 952-965.
- Ubelaker DH** (2000) Forensic Anthropology: methodology and diversity of applications. In *Biological anthropology of the human skeleton* (eds Katzenberg MA, Saunders SR), pp. 41-69. New York: Wiley-Liss.
- Villa C, Buckberry J, Cattaneo C, Frohlich B, Lynnerup N** (2015a) Quantitative Analysis of the Morphological Changes of the Pubic Symphyseal Face and the Auricular Surface and Implications for Age at Death Estimation. *J Forensic Sci* **60**, 556-565.
- Villa C, Buckberry J, Cattaneo C, Lynnerup N** (2013a) Technical note: Reliability of Suchey-Brooks and Buckberry-Chamberlain methods on 3D visualizations from CT and laser scans. *Am J Phys Anthropol* **151**, 158-163.
- Villa C, Gaudio D, Cattaneo C, Buckberry J, Wilson AS, Lynnerup N** (2015b) Surface curvature of pelvic joints from three laser scanners: separating anatomy from measurement error. *J Forensic Sci* **60**, 374-381.
- Villa C, Hansen MN, Buckberry J, Cattaneo C, Lynnerup N** (2013b) Forensic age estimation based on the trabecular bone changes of the pelvic bone using post-mortem CT. *Forensic Sci Int* **233**, 393-402.
- Villa C, Møller Rasmussen M, Lynnerup N** (2011) Age Estimation by 3D CT Scans of the Borremose Woman, a Danish Bog Body. *Am J Phys Anthropol* **1**, 165-169.
- Wade A, Nelson A, Garvin G, Holdsworth DW** (2011) Preliminary radiological assessment of age-related change in the trabecular structure of the human os pubis. *J Forensic Sci* **56**, 312-319.
- Walker RA, Lovejoy CO** (1985) Radiographic changes in the clavicle and proximal femur and their use in the determination of skeletal age at death. *Am J Phys Anthropol* **68**, 67-78.
- Weber GW** (2015) Virtual Anthropology. *American Journal of Physical Anthropology* **156**, 22-42.
- Weber WG, Bookstein FL** (2011) *Virtual Anthropology. A guide to a new interdisciplinary field*, Springer-Verlag Wien, Vienna.
- Wink AE** (2014) Pubic symphyseal age estimation from three-dimensional reconstructions of pelvic CT scans of live individuals. *J Forensic Sci* **59**, 696-702.

Zollikofer CP, Ponce de Leon M (2005) *Virtual Reconstruction: A Primer in Computer-Assisted Paleontology and Biomedicine*, Wiley-Blackwell, New Jersey.




Fig.1 3D segmentation of an auricular surface generated from CT scan with horizontal lines artefacts. CT scans were performed using a Siemens Somatom Sensation 4, 120kV, 200mAs, 1mm slice thickness and 0.3 mm slice increment.

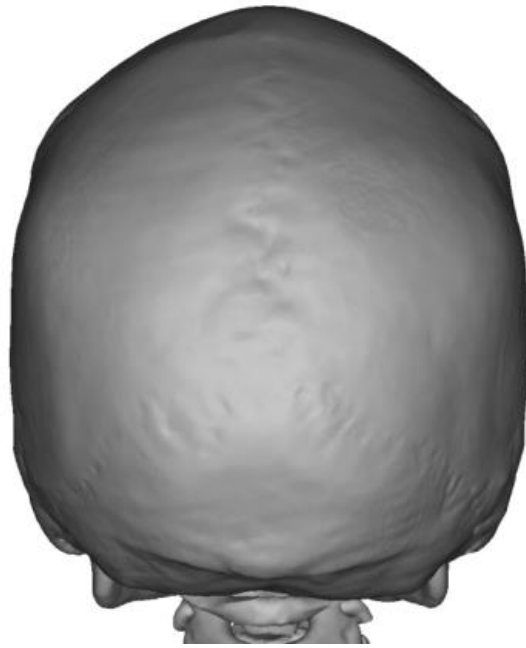

Fig. 2 3D segmentation of the skull of a 24- year-old female generated from CT scans performed with a Siemens Somatom Sensation 4, 120kV, 200mAs, 3mm slice thickness and 2.5 mm slice increment.

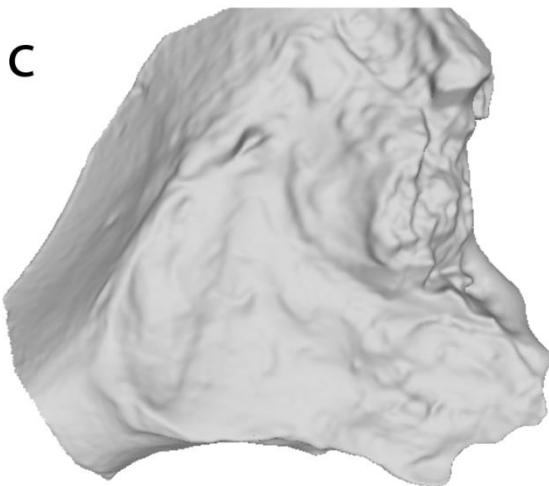
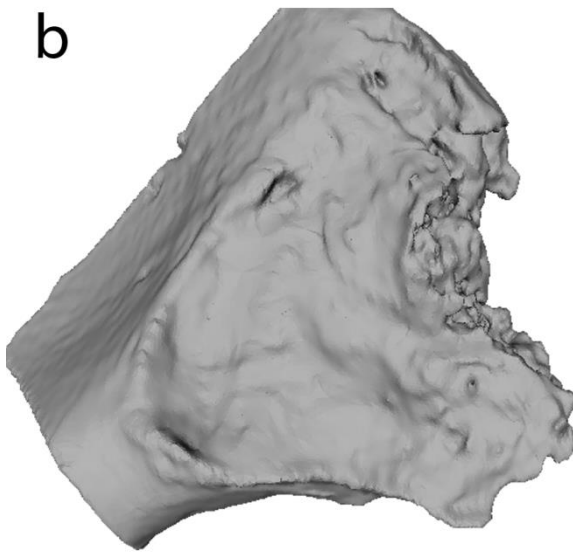



Fig 3. Photograph (a), 3D model from CT scans (b), 3D model from laser scan (c) of the same auricular surface. CT scans were performed using Siemens Somatom Sensation 4 at 120 kV,110

mAs, 0.75 mm slice thickness and 0.3 mm slice increment interval. Laser scanning were obtained using a custom laser scanner with a resolution of 0.1 mm (for more details see Villa et al. 2013)

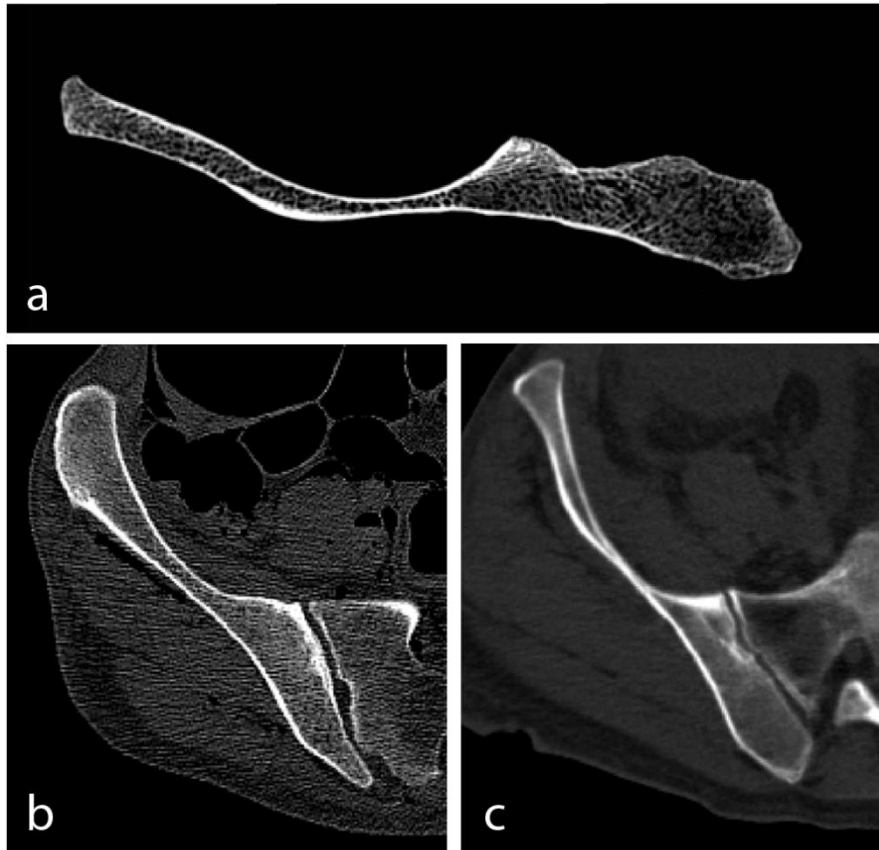


Fig. 4. Visualisation of the trabecular structures in CT images of different specimens and performed with different CT-scanner settings: dry bone scanned with 0.63 mm slice thickness, 0.2mm slice increment and hard reconstruction algorithm (a); cadavers scanned with 3 mm slice thickness, 3mm slice increment and hard reconstruction algorithm (b); and cadavers scanned with 3 mm slice thickness, 3mm slice increment and soft reconstruction (c). CT scans were performed using a Siemens Somatom Sensation 4 CT scanner.

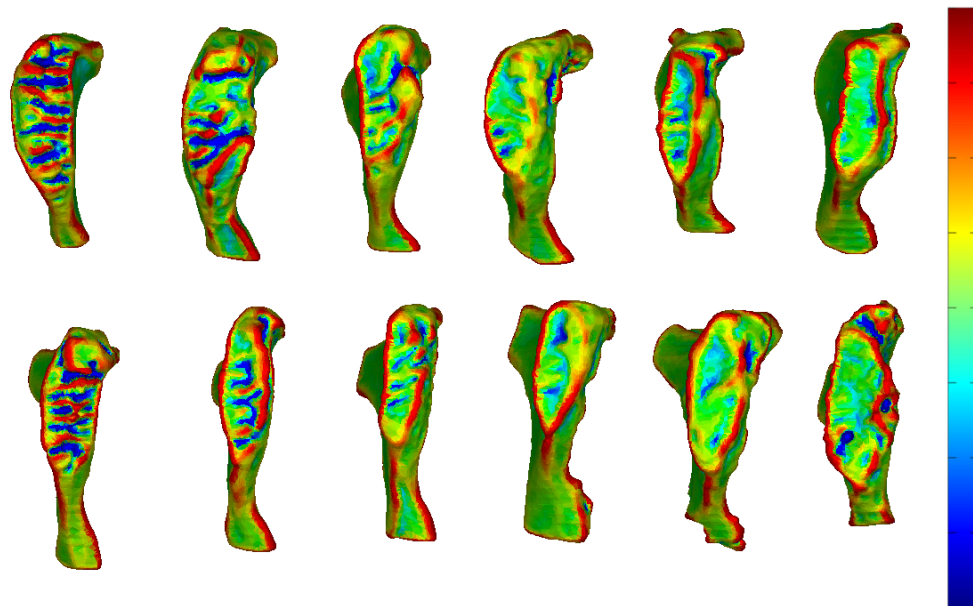


Fig. 5: Colour coded images of the results of the curvature analysis on the female Suchey-Brooks pubic bone casts. In the bar, blue, red and green represent concave, convex and flat surfaces, respectively. The cast was CT scanned with Siemens Somatom Emotion 6 at 130 kV, 90 mAs with 0.63 mm slice thickness and 0.2 mm slice increment.